




Sociedad Española  
de Reumatología -  
Colegio Mexicano  
de Reumatología



## Images in Clinical Rheumatology

### Double Cervical Rib: A Case Report<sup>☆</sup>

#### Doble costilla cervical: a propósito de un caso

Nahia Plaza Aulestia,<sup>\*</sup> Sergio Rodríguez Montero, María Luisa Velloso Feijoo

Servicio de Reumatología, Hospital Universitario Virgen de Valme, Sevilla, Spain

#### ARTICLE INFO

##### Article history:

Received 26 June 2017

Accepted 27 June 2017

Available online 6 November 2018

#### Presentation of the Case

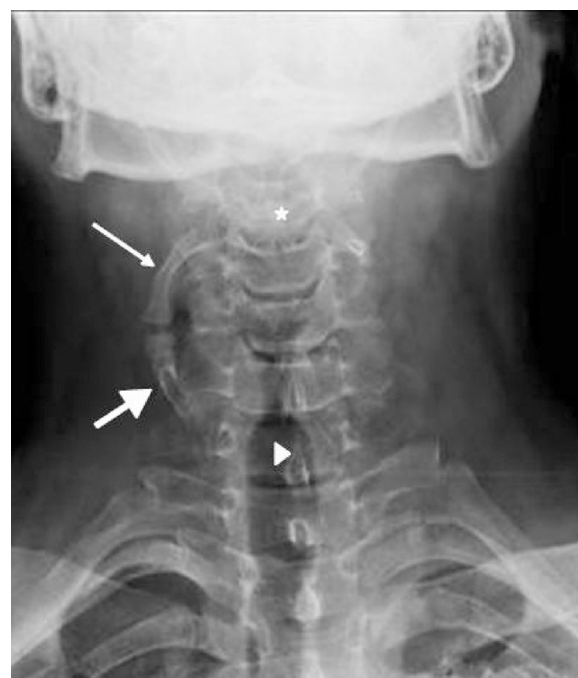A 39-year-old male, recently diagnosed with psoriasis with incomplete response to prescribed treatment (methotrexate 15 mg sc weekly), presenting with pain in the carpi, knees and feet together with morning stiffness of half an hour's duration and paraesthesia in the hands, predominantly at night, of 2–3 months' onset. He also reported neck pain limiting movement, of one month's onset.

Joint examination highlighted synovitis 1st left MCP, 2nd to 4th left PIP, 2nd to 3rd right MCP and 2nd to 4th right PIP. Pain with no swelling 2nd to 4th left MCP. Painful hips, knees and shoulders, with no functional limitation and positive SI opening and closing manoeuvres. Laboratory tests showed slightly increased acute phase reactants (CRP 17.9 and ESR 18), with no other pathological findings, and negative RF, ANA and ANCA.

The plain neck X-ray (Fig. 1) performed on admission showed a proximal cervical rib originating in vertebral body C3 in a caudal direction and articulating with another distal supernumerary rib, originating and ascending from vertebral body C7.

#### Discussion

Cervical ribs are prolongations of the transverse process of the seventh cervical vertebra beyond the transverse process of the first thoracic rib. Their incidence is different in different countries,<sup>1–7</sup> although it is estimated at around between .2% and 8%, and is more common in women.<sup>3,5,7</sup> They can be unilateral or bilateral (the latter comprise 50%–80%), with poor right predominance when they



**Fig. 1.** Proximal cervical rib (thin arrow) originating in vertebral body C3 (star) in a caudal direction and articulating with another distal supernumerary rib (thick arrow) originating and ascending from vertebral body C7 (arrow tip).

are unilateral.<sup>2,8</sup> In 90% of cases they tend to be asymptomatic<sup>3,6–8</sup> and are usually diagnosed accidentally when a plain X-ray of the chest or cervical spine is performed for a different reason. Treatment is usually conservative with rehabilitation, except when symptoms occur caused by nerve (brachial plexus) or vascular

<sup>☆</sup> Please cite this article as: Plaza Aulestia N, Rodríguez Montero S, Velloso Feijoo ML. Doble costilla cervical: a propósito de un caso. Reumatol Clin. 2019;15:370–371.

<sup>\*</sup> Corresponding author.

E-mail address: [nahia.ondarru@hotmail.com](mailto:nahia.ondarru@hotmail.com) (N. Plaza Aulestia).

(subclavian artery) compression,<sup>5–7</sup> when the surgical option is taken.<sup>4</sup>

### Ethical Responsibilities

**Protection of people and animals.** The authors declare that no experiments were performed on humans or animals for this investigation.

**Data confidentiality.** The authors declare that they have followed the protocols of their work centre on the publication of patient data.

**Right to privacy and informed consent.** The authors declare that no patient data appears in this article.

### Conflict of Interests

The authors have no conflicts of interests to declare.

### References

1. Bots J, Wijnaendts L, Denle S, Van Dongen S, Heikinheimo K, Galis F. Analysis of cervical ribs in a series of human fetuses. *J Anat.* 2011;219:403–9.
2. Hershkovitz R. Prenatal diagnosis of isolated abnormal number of ribs. *Ultrasound Obstet Gynecol.* 2008;32:506–9.
3. Viertel VG, Intrapromkul J, Maluf F, Patel NV, Alluwaimi F, Walden MJ, et al. Cervical ribs: a common variant overlooked in CT imaging. *Am J Neuroradiol.* 2012;33:2191–4.
4. Povlsen B, Hansson T, Povlsen SD. Treatment for thoracic outlet syndrome. *Cochrane Database Syst Rev.* 2010. CD007218.
5. Ballesteros Lara T, Martines Montes MA, Delgado Sala A. Costilla cervical en el diagnóstico diferencial de una masa supraclavicular. *Rev Pediatr Aten Primaria.* 2014;16:45–8.
6. Glass R, Norton K, Mitre S, Kang E. Pediatric ribs: a spectrum of abnormalities. *RadioGraphics.* 2002;22:87–104.
7. Brewin J, Hill M, Ellis H. The prevalence of cervical ribs in a London population. *Clin Anat.* 2009;22:331–6.
8. Spadlinski L, Cecot T, Majos A, Stefánczyk L, Pietruszewska W, Wysocki G, et al. The epidemiological, morphological and clinical aspects of the cervical ribs in humans. *BoiMed Res Int.* 2016;2016:1–7.