



Sociedad Española
de Reumatología -
Colegio Mexicano
de Reumatología

Reumatología Clínica

www.reumatologiaclinica.org



Letter to the Editor

Madelung's Deformity[☆]



Deformidad de Madelung

Dear Editor,

We present the case of a 26 year-old Caucasian woman with a history of Crohn's disease currently treated with azathioprine and monitored by gastroenterology. She visited the rheumatology department to rule out enteropathic arthropathy. In the anamnesis she described polyarthralgias in the lumbar spine and hands during the previous 2 years, more in the right carpus with mechanical rhythm. No joint inflammation or morning rigidity. No nocturnal paresthesias. Stable in gastroenterological terms. In the physical examination she had pain when pressure was applied on the right carpus, with the presence of a small tumour in the right dorsal ulna zone, without limitation of mobility or joint inflammation (Fig. 1A and B). She was found to be within normal parameters in the

analytical study, including a haemogram, general biochemistry and autoimmunity.

In the posterior–anterior projection of the both hands and wrists the radiological study found (Fig. 1C) a shortening of the radius in comparison with the ulna, giving rise to an incongruence in the distal radioulnar joint and subluxation of the carpus, as well as the curved radius with dorsal and radial convexity. In the lateral projection (Fig. 1D) anterior arching of the radius can be seen together with dorsal subluxation of the ulna head. Based on the radiological finding the patient was diagnosed with Madelung's deformity.¹ Differential diagnosis was performed to rule out association with other diseases such as carpal tunnel syndrome, Turner's syndrome, small size due to alteration of the SHOX² gene, Hurler's syndrome (mucopolysaccharidosis), achondroplasia and Ollier's disease (multiple enchondromatosis). Treatment was prescribed with paracetamol and non-steroid anti-inflammatory drugs (NSAIDs) on demand to relieve the pain, with a good response.

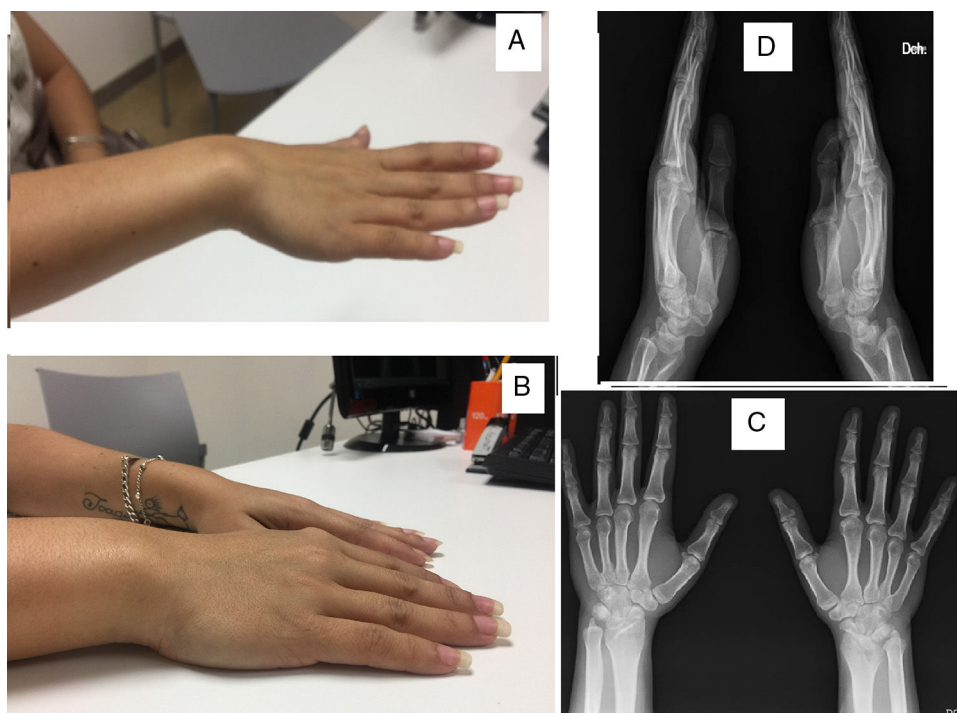


Fig. 1. (A and B) Dorsal dislocation of the ulna. (C) Posterior–anterior X-ray of both hands. (D) Lateral X-ray of both hands.

[☆] Please cite this article as: Añón Oñate I, Pérez Albaladejo L, Ferrer González MÁ, Cáliz Cáliz R. Deformidad de Madelung. Reumatol Clin. 2019;15:e161–e162.

Madelung's deformity has an incidence of 1.7% within the different deformities of the hand, and it is due to a congenital deformity.³ Its symptoms usually commence in adolescent women, with a very slow-growing tumour in the dorsal zone of the ulna in the wrists, as well as local pain and sometimes even a reduction in mobility. In X-rays growth is seen to stop in the distal radial physis with an increase in the angle of the radius (arching) and dorsal subluxation of the distal ulna in the majority of cases.

As regards treatment, we can differentiate between medical treatment and/or surgical treatment. Conservative treatment is the main therapeutic foundation, with analgesics, NSAIDs and muscle relaxants. In the case of Madelung's deformity associated with carpal tunnel syndrome, we may consider local corticosteroid infiltrations. And in very painful cases splints may be recommended to prevent excessive mobilisation of the joint. Surgical treatment^{4,5} is considered in the case of severe deformities with major symptoms, and it would have the aim of relieving pain, aesthetic correction and/or improving mobility.

References

1. Ly-Pen D, Andreu JL. Madelung's deformity. *Reumatol Clin.* 2014;10:125–6.
2. Frederiksen AL, Hansen S, Brixen K, Frost M. Increased cortical area and thickness in the distal radius in subjects with SHOX-gene mutation. *Bone.* 2014;69:23–9.
3. Ulici A, Florea DC, Tevanov I, Zaharie D, Carp M. Surgical treatment of a rare "Reverse" madelung deformity in 11 years female patient. *Chirurgia (Bucur).* 2017;112:72–6.
4. Eric KK, Blaise YL, Leopold KK, Niaore SB, Innocent MK, Arnaud AY, et al. Madelung's deformity: a case report and review of the literature. *Pan Afr Med J.* 2016;23:137.
5. Tranmer A, Laub D. Madelung deformity. *Eplasty.* 2016;16:ic34.

Isabel Añón Oñate,* Lorena Pérez Albaladejo,
Miguel Ángel Ferrer González, Rafael Cáliz Cáliz

*Servicio de Reumatología, Hospital Universitario Virgen de las Nieves,
Granada, Spain*

* Corresponding author.

E-mail address: isaanononate@gmail.com (I. Añón Oñate).