



Sociedad Española
de Reumatología -
Colegio Mexicano
de Reumatología

Reumatología Clínica

www.reumatologiaclinica.org



Letter to the Editor

Treatment of uveitis and ankylosing spondylitis refractory to three tumor necrosis factor alpha inhibitors drugs with golimumab[☆]



Tratamiento de uveítis y espondilitis anquilosante refractoria a tres medicamentos inhibidores de factor de necrosis tumoral alfa con golimumab

Dear Editor,

Uveitis is the most common extra-articular manifestation in patients with spondyloarthritis, and is present in 23% of patients with ankylosing spondylitis, and 15.9% of patients with non-radiographic spondyloarthritis,¹ with a greater risk for HLA-B27-allele-positive patients with an OR of 4.2 (3.3–5.3).² It presents in up to 41% as a first manifestation of spondyloarthritis, and the 2 key characteristics to aid diagnosis are the presence of anterior recurring uveitis, and back or joint pain.³ The most common presentation of uveitis is acute in 88.7%, it is anterior in 90.5%, and unilateral in 87.3%.² Its management includes topical mydriatic agents, sulfasalazine and methotrexate to reduce recurrence.⁴ Treatment with tumor necrosis factor blockers (anti-TNF α) is effective in improving the signs and symptoms of spondyloarthritis and uveitis,⁵ and there are recommendations on the use of monoclonal antibodies such as infliximab and adalimumab as first-line anti-TNF α agents to treat uveitis associated with spondyloarthritis.^{6,7} However, there are no recommendations on the management of patients for whom this strategy fails.

We present the case of a 37-year-old woman who presented with a 2-year history of inflammatory lumbar pain; she had a history of an episode of anterior uveitis 8 years earlier in the left eye, which improved with topical management, within extension studies with the presence of HLA-B27, high acute phase reactants, and grade 2 bilateral sacroiliitis found on conventional radiography; a diagnosis was made of ankylosing spondylitis. Management with NSAIDs, methotrexate and sulfasalazine was started, presenting liver and skin toxicity. Due to persistent inflammatory lumbar pain with a BASDAI score of 7, and elevated acute phase reactants, the patient was started on etanercept; two years later she presented with uveitis in the right eye and recurrence of her inflammatory lumbar pain. Following the therapeutic failure of infliximab and adalimumab due to recurrence of the uveitis episodes, the patient is being managed with monthly subcutaneous golimumab; clinical improvement of joint disease activity has been achieved and she has had no further episodes of uveitis.

For patients with spondyloarthritis with episodes of refractory uveitis (as in the case we present), the guidelines of the American College of Rheumatology (ACR)⁷ recommend the use of anti-TNF α monoclonal antibodies (infliximab, adalimumab) versus fusion proteins (etanercept) to reduce the recurrence of uveitis.

Similarly, the guidelines of the European League Against Rheumatism (EULAR) on axial spondyloarthritis⁶ mention that infliximab, adalimumab and certolizumab are effective in preventing uveitis recurrence, while the results with etanercept remain contradictory; to date there have been no published cases on the effectiveness of golimumab for refractory uveitis associated with spondyloarthritis. Likewise on the management of anti-TNF α agents, ophthalmology⁸ continue to recommend infliximab and adalimumab rather than etanercept, as second-line immunomodulatory agents for inflammatory eye disorders, including posterior uveitis, panuveitis and severe uveitis associated with spondyloarthritis. A recent study by Calvo-Río et al.,⁹ in which golimumab was used for 15 patients with uveitis associated with spondyloarthritis refractory to at least one immunosuppressive drug, reported an improvement in intraocular inflammatory parameters using this therapeutic strategy. On reviewing the study, only one patient shared similar characteristics with our patient, namely, failure of the same anti-TNF α agents (infliximab, adalimumab and etanercept). The study by Yazgan et al.,¹⁰ which assessed the use of golimumab for patients with HLA-B27-positive ankylosing spondylitis and recurrent anterior uveitis found complete remission of the ocular involvement, and significantly increased visual acuity ($P=.002$). None of the patients described in this study had similar characteristics to our patient. Therefore our case reinforces the efficacy of golimumab for patients with refractory and recurrent uveitis associated with spondyloarthritis who have already been treated with other anti-TNF α drugs.

References

1. De Winter JJ, van Mens LJ, van der Heijde D, Landewé R, Baeten DL. Prevalence of peripheral and extra-articular disease in ankylosing spondylitis versus non-radiographic axial spondyloarthritis: a meta-analysis. *Arthritis Res Ther.* 2016;18:196.
2. Zeboulon N, Dougados M, Gossec L. Prevalence and characteristics of uveitis in the spondyloarthropathies: a systematic literature review. *Ann Rheum Dis.* 2008;67:955–9.
3. Fernández-Melón J, Muñoz-Fernández S, Hidalgo V, Bonilla-Hernán G, Schlincker A, Fonseca A, et al. Uveitis as the initial clinical manifestation in patients with spondyloarthropathies. *J Rheumatol.* 2004;31:524–7.
4. Khan MA, Haroon M, Rosenbaum JT. Acute anterior uveitis and spondyloarthritis: more than meets the eye. *Curr Rheumatol Rep.* 2015;17:59.
5. Guignard S, Gossec L, Salliot C, Ruysen-Witrand A, Luc M, Duclos M, et al. Efficacy of tumour necrosis factor blockers in reducing uveitis flares in patients with spondyloarthritis: a retrospective study. *Ann Rheum Dis.* 2006;65:1631–4.
6. Van der Heijde D, Ramiro S, Landewé R, Baraliakos X, van den Bosch F, Sepriano A, et al. 2016 update of the ASAS-EULAR management recommendations for axial spondyloarthritis. *Ann Rheum Dis.* 2017;1–14.
7. Ward MM, Deodhar A, Akl EA, Lui A, Ermann J, Gensler LS, et al. American College of Rheumatology/Spondylitis Association of America/Spondyloarthritis Research and Treatment Network 2015 recommendations for the treatment of ankylosing spondylitis and nonradiographic axial spondyloarthritis. *Arthritis Rheumatol.* 2016;68:282–98.
8. Levy-Clarke G, Jabs DA, Read RW, Rosenbaum JT, Vitale A, van Gelder RN. Expert panel recommendations for the use of anti-tumor necrosis factor biologic agents in patients with ocular inflammatory disorders. *Ophthalmology.* 2014;121, 785–96.e3.
9. Calvo-Río V, Blanco R, Santos-Gomez M, Rubio-Romero E, Cordero-Coma M, Gallego-Flores A, et al. Golimumab in refractory uveitis related to spondyloarthritis. Multicenter study of 15 patients. *Semin Arthritis Rheum.* 2016;46:95–101.
10. Yazgan S, Celik U, Işık M, Yeşil NK, Baki AE, Şahin H, et al. Efficacy of golimumab on recurrent uveitis in HLA-B27-positive ankylosing spondylitis. *Int Ophthalmol.* 2017;37:139–45.

[☆] Please cite this article as: Chaparro Sanabria JA, Bautista Molano W, Valle Oñate R. Tratamiento de uveítis y espondilitis anquilosante refractoria a tres medicamentos inhibidores de factor de necrosis tumoral alfa con golimumab. *Reumatol Clin.* 2020;16:64–65.

Jeimy Andrea Chaparro Sanabria,^{a,b,*} Wilson Bautista Molano,^c
Rafael Valle Oñate^{b,d}

^d Reumatólogo, Hospital Militar Central, Bogotá, Colombia

^a Universidad Militar Nueva Granada, Bogotá, Colombia

^b Servicio de Reumatología, Hospital Militar Central, Bogotá, Colombia

^c Facultad de Medicina, Universidad Militar Nueva Granada, Bogotá, Colombia

* Corresponding author.

E-mail address: annychs@gmail.com (J.A. Chaparro Sanabria).

2173-5743/ © 2018 Elsevier España, S.L.U. and Sociedad Española de Reumatología y Colegio Mexicano de Reumatología. All rights reserved.

Shrinking lung syndrome and pleural effusion as an initial manifestation of primary Sjögren's syndrome[☆]



Síndrome de pulmón encogido y derrame pleural como manifestación inicial de síndrome de Sjögren primario

Dear Editor,

Shrinking lung syndrome (SLS) and pleural effusion (PE) are rare manifestations of primary Sjögren's syndrome (pSS).^{1,2} We present the case of a female patient with these manifestations of the onset of pSS.

A 50-year-old woman who consulted with a 4-week history of dyspnoea on medium exertion, right-sided pleuritic pain and constitutional symptoms. Two weeks prior to admission she underwent a chest X-ray showing mild PE, and infectious and tumour

processes were ruled out. Due to the persistent symptoms a repeat chest X-ray was performed which showed elevation of both hemidiaphragms and bibasilar laminar atelectasis (Fig. 1A and B). CT scan and chest angiotomography confirmed atelectasis, right-sided PE, with no infiltrates or pulmonary emboli (Fig. 1C and D). Reduced bilateral diaphragmatic excursion was observed on fluoroscopy (sniff test). Thoracentesis was performed; the fluid was compatible with exudate. Severe restriction and reduced maximum inspiratory and expiratory pressures were observed. There was reduced carbon monoxide diffusion capacity. The six-minute walking test showed a 5-point drop in oxygen saturation after 2 min. The patient initially denied the presence of sicca symptoms. Mild leukocytosis was observed, elevated erythrocyte sedimentation rate, polyclonal hypergammaglobulinaemia, and viral serologies were negative. Prednisone 20 mg/day was started until the immunological results were available. ANA-Hep2, anti-ENA, anti-Ro/SS-A,

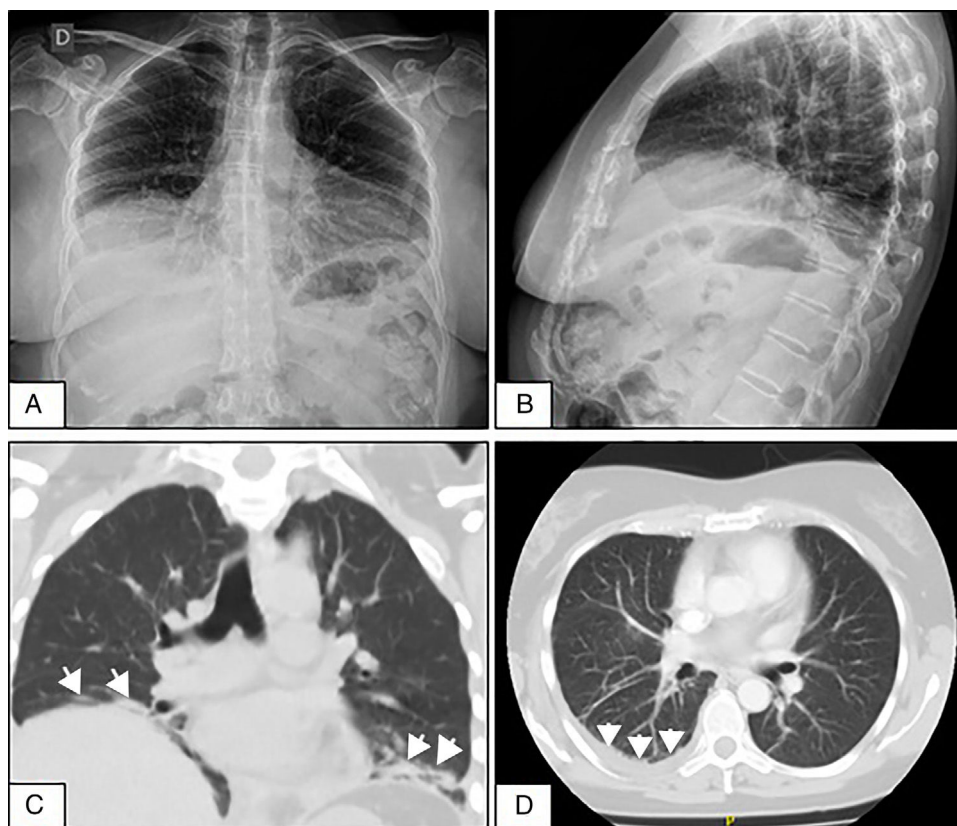


Fig. 1. (A and B) Front and side-view chest X-rays showing the elevation of both hemidiaphragms and bibasilar laminar atelectasis. (C) Coronal CT without contrast material showing diaphragmatic elevation and subsegmental atelectasis (arrows) in both lung bases. (D) Axial CT of the chest with contrast material showing slight pleural effusion in the right lung base (arrows).

[☆] Please cite this article as: Baenas DF, Retamozo S, Pirola JP, Caeiro F. Síndrome de pulmón encogido y derrame pleural como manifestación inicial de síndrome de Sjögren primario. Reumatol Clin. 2020;16:65–68.