

3. Tristano AG. Acquired amegakaryocytic thrombocytopenic purpura: review of a not very well-defined disorder. *Eur J Intern Med.* 2005;16:477–81. <http://dx.doi.org/10.1016/j.ejim.2005.04.014>
4. Kuwana M, Kaburaki J, Okazaki Y, Miyazaki H, Ikeda Y. Two types of autoantibody-mediated thrombocytopenia in patients with systemic lupus erythematosus. *Rheumatology.* 2006;45:851–4. <http://dx.doi.org/10.1093/rheumatology/ke1010>
5. Kuwana M, Okazaki Y, Kajihara M, Kaburaki J, Miyazaki H, Kawakami Y, et al. Autoantibody to c-Mpl (thrombopoietin receptor) in systemic lupus erythematosus: relationship to thrombocytopenia with megakaryocytic hypoplasia. *Arthritis Rheum.* 2002;46:2148–59. <http://dx.doi.org/10.1002/art.10420>
6. Nagasawa T, Sakurai T, Kashiwagi H, Abe T. Cell-mediated amegakaryocytic thrombocytopenia associated with systemic lupus erythematosus. *Blood.* 1986;67:479–83. Available from: <https://www.ncbi.nlm.nih.gov/pubmed/3484642>
7. Griner PF, Hoyer LW. Amegakaryocytic thrombocytopenia in systemic lupus erythematosus. *Arch Intern Med.* 1970;125:328–32. Available from: <https://www.ncbi.nlm.nih.gov/pubmed/5412024>
8. Chalayer E, Costedoat-Chalumeau N, Beyne-Rauzy O, Ninet J, Durupt S, Tebib J, et al. Bone marrow involvement in systemic lupus erythematosus. *QJM.* 2017. <http://dx.doi.org/10.1093/qjmed/hcx102>
9. Pereira RM, Velloso ER, Menezes Y, Gualandro S, Vassalo J, Yoshinari NH. Bone marrow findings in systemic lupus erythematosus patients with peripheral cytopenias. *Clin Rheumatol.* 1998;17:219–22. Available from: <https://www.ncbi.nlm.nih.gov/pubmed/9694056>
10. Chang H, Tang TC. Successful treatment of amegakaryocytic thrombocytopenia with azathioprine. *Acta Haematol.* 2011;126:135–7. <http://dx.doi.org/10.1159/000328031>

Latika Gupta^a, Vikas Gupta^{a,*}, Krushna Chandra Pani^b, Navkirti Mittal^c, Vikas Agarwal^a

^a Department of Clinical Immunology, Sanjay Gandhi Postgraduate Institute of Medical Sciences, Lucknow, Uttar Pradesh, India

^b Department of Pathology, Sanjay Gandhi Postgraduate Institute of Medical Sciences, Lucknow, Uttar Pradesh, India

^c Department of Hematology, Sanjay Gandhi Postgraduate Institute of Medical Sciences, Lucknow, Uttar Pradesh, India

* Corresponding author.

E-mail address: vikasgcapri@yahoo.co.in (V. Gupta).

<https://doi.org/10.1016/j.reuma.2018.03.005>

1699-258X/ © 2018 Elsevier España, S.L.U. and Sociedad Española de Reumatología y Colegio Mexicano de Reumatología. All rights reserved.

Cervical abscess as an exceptional presentation of advance bisphosphonate-related osteonecrosis of the jaw: Case report and review of the literature[☆]



Absceso cervical como forma de presentación excepcional de osteonecrosis mandibular avanzada inducida por bisfosfonatos. A propósito de un caso y revisión de la literatura

Dear Editor,

Bisphosphonates (BPP) are a group of synthetic analogous drugs of inorganic pyrophosphate used intravenously in the treatment of different oncological processes and in solid tumour bone metastasis (breast, prostate and lung), which do not increase survival but have been demonstrated to raise quality of life.¹ However, they present the serious side effect of inducing osteonecrosis of the jaw (ONJ).

We present the case of a Caucasian woman aged 65 with no toxic substance (tobacco) habits or medical history of interest (diabetes, chronic intake of corticoids, etc.), but with the added risk factor of impaired dental status (many root remnants) and active periodontal disease. She was diagnosed in 2013 with stage IV advanced breast cancer (CT4N2bMx) which required surgical intervention (tumorectomy and axillary node dissection), and treatment was completed with radiotherapy (RT) and polychemotherapy. After successive controls, in 2014 a bone scan detected metastatic foci on the right ala of the sacrum and the spine, with severe pain. Treatment was initiated with intravenous BPP (zoledronic Acid, Zometa[®] 4mg/3 weeks). The patient was treated in our unit in 2015 because she spontaneously presented with a right submandibular abscess (Fig. 1) which was initially drained under local anaesthesia, obtaining 150 mL of purulent, cheese-like material, which tested positive for *Actinomyces israelii*. She was subsequently admitted to hospital for examination and treatment with

broad spectrum antibiotics for the condition and for pain management. Although the intraoral examination did not reveal any findings of interest, the CAT scan showed the existence of a wide area of osteonecrosis in the right half of the jaw region (Fig. 2). After medical treatment for one week (amoxicillin 1g/8h and daily mouthwashes every 8h with chlorhexidine 2% solution), the patient underwent surgery with a general anaesthesia, with extensive curettage of the wound. Highly favourable medical evolution proceeded until her death in 2017 from the baseline neoplastic process.

BPP-induced ONJ has been widely covered in the scientific literature, but despite the fact there are numerous publications which attempt to explain its aetiopathology, is aetiopathogenic mechanism has not yet been fully defined.² At present there are 4 stages to classify ONJ, according to the regulations established by the American Association of Oral and Maxillofacial Surgeons, with the presented case corresponding to the most advanced stage (stage 3).³ In the case presented zoledronate (Zometa[®]) is considered to be the most powerful BPP, 100 times superior to pamidronate, having demonstrated with its use that the appearance of ONJ is higher and earlier than that of other BPP, with intravenous administration of them being the main factor of risk for the appearance of ONJ. The most normal form of presentation of ONJ is progressive, both clinically and radiographically and the presented case is therefore exceptional although several authors such as Kaehling et al.⁴ and Soda et al.⁵ have communicated different case of thromboembolism of the internal jugular vein and subsequent sepsis in the first case and retropharyngeal abscess in the second, as the form of presentation of the ONJ. The explanation lies in super infection of the bone by different pathogenic agents, with the main one being *A. israelii*, and in the action of the BPP on the adjacent soft tissues.

To conclude, the possibility of developing an ONJ has to always be contemplated in patients at risk (oncological patients who have previously been treated with RT), despite its unusual presentation in the form of an abscess, the appearance of it is a relevant data in clinical suspicion of ONJ, requiring personalized treatment, depending on the clinical and radiographic findings of the patient.

[☆] Please cite this article as: Sánchez López JD, Cariati P, Rodríguez I, Carriel Araya S. Absceso cervical como forma de presentación excepcional de osteonecrosis mandibular avanzada inducida por bisfosfonatos. A propósito de un caso y revisión de la literatura. *Reumatol Clin.* 2020;16:250–251.

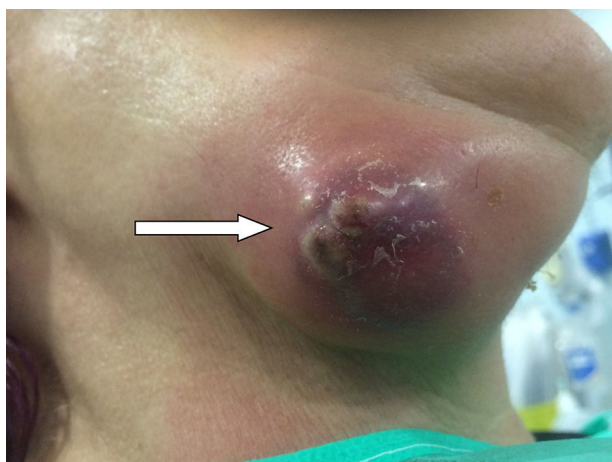

Fig. 1. Massive right submandibular abscess (white arrow).

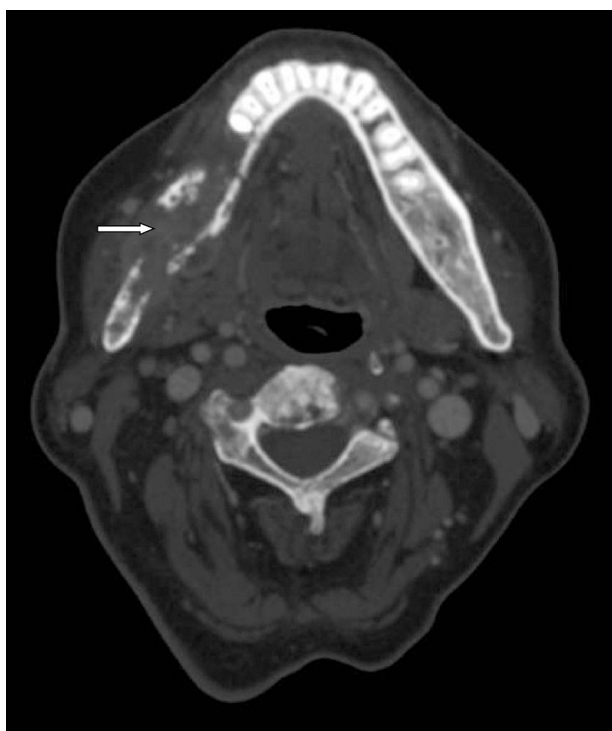


Fig. 2. Extensive area of osteonecrosis in right half jaw region (white arrow).

References

1. Schröder J, Fietz T, Köhler A, Petersen V, Tesch H, Spring L, et al. Treatment and pattern of bone metastases in 1094 patients with advanced breast cancer – results from the prospective German Tumour Registry Breast Cancer cohort study. *Eur J Cancer*. 2017;79:139–48.
2. Khoo TK. Bisphosphonates and osteonecrosis of the jaw. *Mayo Clin Proc*. 2017;92:1166–7.
3. Ruggiero S, Dodson T, Fantasia J, Goodday R, Aghaloo T, Mehrotra B, et al. American association of oral and maxillofacial surgeons position paper on medication-related osteonecrosis of the jaw – 2014 update. *J Oral Maxillofac Surg*. 2014;72:1938–56.
4. Kaehling C, Streckbein P, Schmermund D, Henrich M, Burchert D, Gattenloehner S, et al. Lethal cervical abscess following bisphosphonate related osteonecrosis of the jaw. *J Craniomaxillofac Surg*. 2014;42:1203–6.
5. Soda T, Fukumoto R, Hayashi T, Oka D, Fujimoto N, Koide T. Case of prostate cancer associated with bisphosphonate-related osteonecrosis of the jaw followed by retropharyngeal abscess [Article in Japanese]. *Hinyokika Kiyo*. 2013;59:587–91.

José Darío Sánchez López^{a,*}, Paolo Cariati^a, Ismael Rodríguez^b, Sebastián Carriel Araya^c

^a Servicio de Cirugía Oral y Maxilofacial, Complejo Hospitalario Universitario de Granada, Granada, Spain

^b Departamento de Cirugía Oral, Facultad de Odontología de la Universidad de Córdoba, Córdoba, Argentina

^c Departamento de Histología, Facultad de Medicina de Granada, Granada, Spain

* Corresponding author.

E-mail address: josed.sanchez.sspa@juntadeandalucia.es (J.D. Sánchez López).

<https://doi.org/10.1016/j.reumae.2018.03.004>

2173-5743/ © 2018 Elsevier España, S.L.U. and Sociedad Española de Reumatología y Colegio Mexicano de Reumatología. All rights reserved.