



Sociedad Española
de Reumatología -
Colegio Mexicano
de Reumatología

Reumatología Clínica

www.reumatologiaclinica.org



Letter to the Editor

Linear atrophy and hypopigmentation after intralesional corticosteroid injection[☆]



Atrofia e hipopigmentación lineal cutánea por inyección intraarticular de corticosteroide

Dear Editor,

The presence of hypopigmented lesions on a patient is a diagnostic challenge. The causes of the lesions can vary, from the cutaneous manifestation of systemic diseases to local reactions to external agents.

We present the case of a 53-year-old female that came to the consultation because of a hypopigmented, depressed skin patch of 2 months' evolution on her left arm (Fig. 1). Relevant medical history included chronic migraine, idiopathic hyperprolactinemia and

epicondylitis in both elbows. Her habitual treatment consisted of amitriptyline, paracetamol and also periodic intra-articular injections of triamcinolone in the 2 elbows—the last having been given 5 months before this consultation. The patient did not report any other relevant signs or symptoms. Examination revealed a hypopigmented atrophic skin patch on the left elbow that extended linearly along the inner side of the upper arm.

Cutaneous biopsy revealed atrophy of the epidermis. The dermis looked normal, without any associated sclerosis, changes in the adnexa or notable inflammatory infiltrates. No significant reduction was seen in the number of melanocytes.

Given the clinical–histological findings, the diagnosis was linear skin hypopigmentation and atrophy after intra-articular injection of triamcinolone acetonide. The patient presented progressive improvement of the lesion until its complete resolution was seen at 8 months of follow-up.

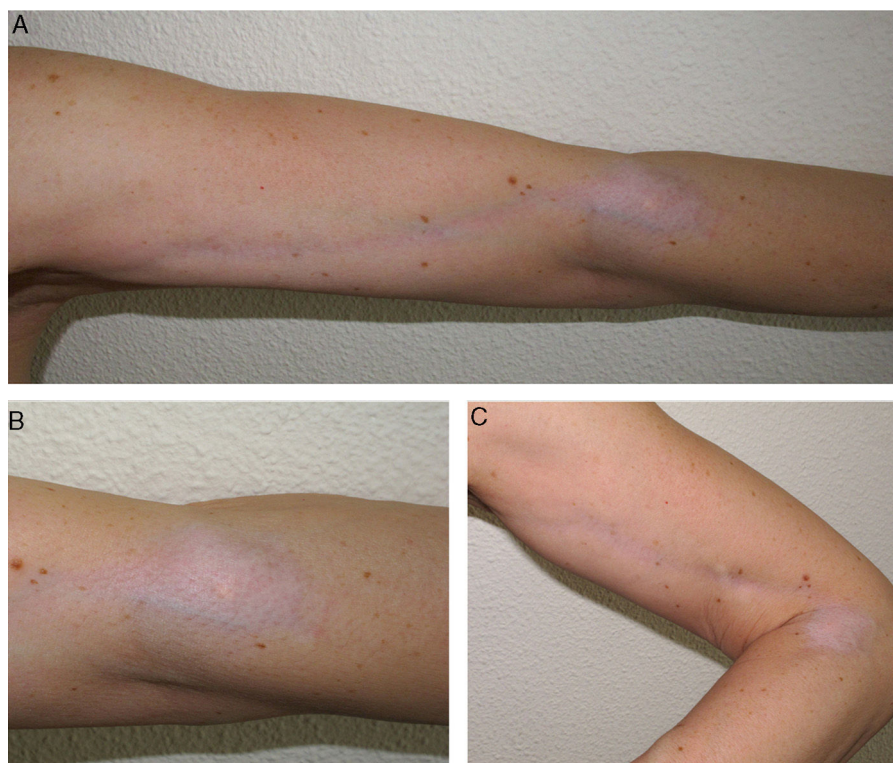


Fig. 1. (A–C) Hypopigmented atrophic patch on the elbow, with linear extension along the upper arm.

[☆] Please cite this article as: Hernández Aragüés I, Villanueva Álvarez-Santullano CA, Suárez Fernández R, Pulido Pérez A. Atrofia e hipopigmentación lineal cutánea por inyección intraarticular de corticosteroide. Reumatol Clin. 2019;15:e72–e73.

Intralesional injection of corticosteroids is very common in standard clinical practice.^{1–3} This practice concentrates more of the drug in the area with a better safety profile, avoiding some of the characteristic systemic side effects, such as iatrogenic Cushing syndrome and the suppression of the hypothalamic–pituitary axis.

Linear hypopigmentation following intralesional or intra-articular injection of corticoids has been described many times, usually associated with the use of triamcinolone acetonide.⁴ A similar condition was recently described in a patient with chronic foot eczema, who had applied a high-strength corticoid topically.⁵ In a series of 440 paediatric patients that were given intra-articular injections of triamcinolone acetonide or methylprednisolone acetate, slightly less than 2% of the patients later developed cutaneous hypopigmentation or atrophy in the injection area.⁶

The condition usually presents as an atrophic and hypopigmented skin patch with branching edges in the injection area; there is also linear extension of the lesion towards the perilesional area, normally following a pattern of lymphatic distribution. Differential diagnosis against other conditions such as linear morphea (localised scleroderma) or eosinophilic fasciitis should be considered, given the similarity in the clinical presentation of the condition that is described here.

This condition manifests after a variable length of time, which can range from weeks to months, following the injection. It can appear after either a single injection or following multiple injections, above all if quantities more than 10 mg/ml are injected.

Skin atrophy from corticosteroids is due to their anti-proliferative effect on fibroblasts and keratinocytes, as well as from alterations in lipid synthesis and in the metabolism of extracellular matrix proteins. The mechanism behind hypopigmentation is less known; it might be due to an alteration in melanocyte secretion, without totally destroying the melanocytes.³

The linear extension that is a feature of this condition probably stems from dispersion through the lymphatic system. Kikuchi and Horikawa⁷ demonstrated this distribution after injecting colouring agents such as blue dye in the initial site of the lesion and confirming its later extension through the lymph vessels.

There is no specific treatment. However, avoiding new injections is generally recommended. It usually takes months after condition

onset for the hypopigmentation to disappear and the skin atrophy to improve.

Acknowledgements

We would like to thank Dr. Verónica Parra Blanco for the histopathological study.

References

1. Cantürk F, Cantürk T, Aydın F, Karagöz F, Sentürk N, Turanlı AY. Cutaneous linear atrophy following intralesional corticosteroid injection in the treatment of tendonitis. *Cutis*. 2004;73:197–8.
2. Venkatesan P, Fangman WL. Linear hypopigmentation and cutaneous atrophy following intra-articular steroid injections for de Quervain's tendonitis. *J Drugs Dermatol*. 2009;8:492–3.
3. Dhawan AK, Bisherwal K, Grover C, Tanveer N. Linear leucoderma following intralesional steroid: a report of three cases. *J Cutan Aesthetic Surg*. 2015;8:117–9.
4. Jang WS, Park J, Yoo KH, Han TY, Li K, Seo SJ, et al. Branch-shaped cutaneous hypopigmentation and atrophy after intralesional triamcinolone injection. *Ann Dermatol*. 2011;23:111–4.
5. Kwon HH, Suh DH. Linear extensions of hypopigmentation as a side effect of topical corticosteroid application. *Int J Dermatol*. 2016;55:e315–7.
6. Lanni S, Bertamino M, Consolaro A, Pistorio A, Magni-Manzoni S, Galasso R, et al. Outcome and predicting factors of single and multiple intra-articular corticosteroid injections in children with juvenile idiopathic arthritis. *Rheumatology*. 2011;50:1627–34.
7. Kikuchi I, Horikawa S. Perilymphatic atrophy of the skin. *Arch Dermatol*. 1975;11:795–6.

Ignacio Hernández Aragüés,^{a,*}

C. Ana Villanueva Álvarez-Santullano,^b Ricardo Suárez Fernández,^b
Ana Pulido Pérez^b

^a *Servicio de Dermatología, Hospital San Pedro, Logroño, La Rioja, Spain*

^b *Servicio de Dermatología, Hospital General Universitario Gregorio Marañón, Madrid, Spain*

* Corresponding author.

E-mail address: ignaciohdezaragues@gmail.com

(I. Hernández Aragüés).