



Sociedad Española
de Reumatología -
Colegio Mexicano
de Reumatología

Reumatología Clínica

www.reumatologiaclinica.org



Images in Clinical Rheumatology

Pachydermodactyly: The great mimicker[☆]

Paquidermodactilia: la gran simuladora

José Luis Agudo-Mena,^{a,*} María Isabel Buedo-Rubio,^b Eva María García-Atienza,^c
Eduardo Escario-Travesedo^a

^a Servicio de Dermatología, Complejo Hospitalario Universitario de Albacete, Albacete, Spain

^b Servicio de Pediatría, Complejo Hospitalario Universitario de Albacete, Albacete, Spain

^c Gerencia de Atención Integrada, Centro de Salud Zona VIII, Albacete, Spain



ARTICLE INFO

Article history:

Received 1 April 2017

Accepted 13 July 2017

Available online 12 September 2019

Clinical case

A 14-year-old male, with no history of interest, consulting with a year's history of deformity and symmetrical pattern swelling on the lateral face of the proximal interphalangeal joints (IPJ) of the second, third and fourth fingers, with predominance in the right hand (Fig. 1A and B). He reported no pain, limitation or other associated skin or systemic manifestations.

Analysis, which included complete blood count, biochemistry, coagulation, erythrocyte sedimentation rate, C reactive protein, HLA-B27, rheumatoid factor and antinuclear antibodies, was normal or negative. Plain X-ray showed an increase in soft tissue on the second, third and fourth IPJ of the right hand, with no signs of associated joint or bone involvement (Fig. 2). Magnetic resonance imaging showed oedema and increased soft tissue on the second, third and fourth fingers of the right hand. There were no signs of synovitis or associated collections (Fig. 3). A skin biopsy was performed that revealed compact hyperkeratosis and thickening of the dermis, with an increase in the number of collagen fibres and fibroblasts.

This led to a diagnosis of classical pachydermodactyly; given the benign nature of this entity and the absence of associated

clinical symptoms a wait-and-see approach was decided. After 18 months of six-monthly follow-up in the paediatric dermatology and rheumatology clinic, the patient remains asymptomatic, without pain, functional limitation or other associated clinical manifestations.

Discussion

Paquidermodactyly, initially described in 1973¹ and later in 1975,² is an acquired and under-diagnosed form of digital fibromatosis, of benign course and predominantly affects young males. It is characterised by the presence of progressive, asymptomatic and bilateral swelling of the IP joints of both hands.^{1–3} The cause is unknown, although the possible implication of repeated micro trauma, genetic and hormonal factors has been postulated.^{4,5} Diagnosis of this entity is essentially clinical, and must be differentiated from juvenile idiopathic arthritis, with characteristic clinical, analytical and radiological findings.^{4–6} Clinical treatment measures are preferred, although intralesional glucocorticoids could be used, and surgery as an alternative in some subgroups of patients.^{3–6}

[☆] Please cite this article as: Agudo-Mena JL, Buedo-Rubio MI, García-Atienza EM, Escario-Travesedo E. Paquidermodactilia: la gran simuladora. Reumatol Clin. 2019;15:e156–e157.

* Corresponding author.

E-mail address: agudo.mena@gmail.com (J.L. Agudo-Mena).

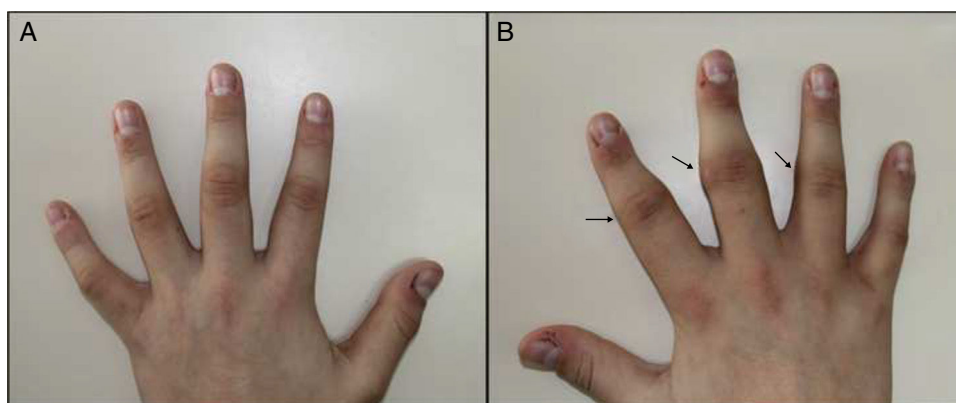


Fig. 1. (A, B) Deformity and swelling on the lateral face of the IPJ of the second, third and fourth fingers, with predominance on the right hand (arrows).

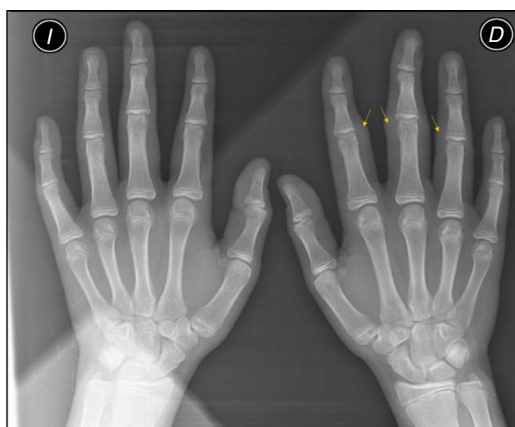

Fig. 2. Radiographic image with increase in soft tissues on the second, third, and fourth IPJ of the right hand, with no signs of associated joint or bone involvement (arrows).

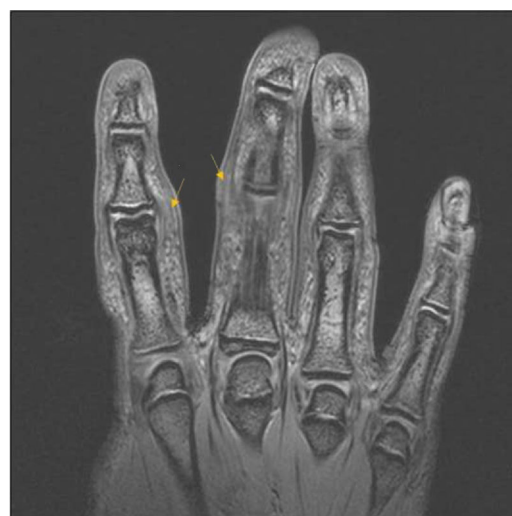

Fig. 3. MRI of right hand, showing an increase in soft tissue with altered signal due to oedema of the second, third and fourth fingers (arrows).

Ethical responsibilities

Protection of people and animals. The authors declare that neither human nor animal testing has been carried out under this research.

Data confidentiality. The authors declare that they have complied with their work centre protocols for the publication of patient data.

Right to privacy and informed consent. The authors have obtained the informed consent of the patients and/or subjects referred to in the article. This document is held by the corresponding author.

Conflict of interests

The authors have no conflict of interest to declare.

References

1. Bazex A, Dupre A, Teillard J. Pachydermie digitale des premières phalanges par hyperplasie conjonctive dermique et aplasie hypodermique. *Bull Soc Fr Dermatol Syphiligr.* 1973;80:455–8.
2. Verbov J. Letter: Pachydermodactyly. A variant of the true knuckle pad. *Arch Dermatol.* 1975;111:524.
3. Plana A, Bassas J, Toro MA, Ferrandiz C. Paquidermodactilia tratada con éxito con infiltraciones de triamcinolona. *Actas Dermosifiliogr.* 2014;105:319–21.
4. Seo SH, Sung HW. A case of pachydermodactyly. *Ann Dermatol.* 2011;23:258–61.
5. Carrascosa R, Godoy A, Gordillo C, de Argila D. Paquidermodactilia en un paciente con trastorno de ansiedad generalizada asociado a tics. *Actas Dermosifiliogr.* 2014;105:625–6.
6. Mesa del Castillo P, Martínez T, de la Peña J, Díaz MC. Paquidermodactilia clásica. *An Pediatr (Barc).* 2016;85:275–6.