



Sociedad Española
de Reumatología -
Colegio Mexicano
de Reumatología

Reumatología Clínica

www.reumatologiaclinica.org



Case Report

Haemothorax in vascular Ehlers-Danlos syndrome[☆]

Kevin Álvarez,^{a,*} Jordi López,^b Jose Angel Hernández^c

^a Servicio de Cardiología, Complejo Hospitalario Universitario Insular-Materno Infantil, Las Palmas de Gran Canaria, Las Palmas, Spain

^b Servicio de Neumología, Complejo Hospitalario Universitario Insular-Materno Infantil, Las Palmas de Gran Canaria, Las Palmas, Spain

^c Servicio de Reumatología, Complejo Hospitalario Universitario Insular-Materno Infantil, Las Palmas de Gran Canaria, Las Palmas, Spain



ARTICLE INFO

Article history:

Received 11 July 2017

Accepted 10 August 2017

Available online 17 September 2019

Keywords:

Ehlers-Danlos syndrome

EDS IV

Vascular Ehlers-Danlos syndrome

ABSTRACT

Vascular Ehlers-Danlos syndrome (EDS IV) is a rare genetic disorder characterised by an alteration in the COL3A1 gene which encodes type III collagen. It is the most common type of collagen in vessels of medium size and certain organs such as the intestines and the uterus. The alteration of this type of collagen produces aneurisms and ruptures of vessels and organs. A high level of clinical suspicion is required for diagnosis. It is a complex disease whose management requires a multidisciplinary team to treat the different complications that may occur.

We report the case of a 50-year-old man diagnosed with EDS IV detected incidentally after haemothorax secondary to a coughing spell.

© 2017 Elsevier España, S.L.U. and Sociedad Española de Reumatología y Colegio Mexicano de Reumatología. All rights reserved.

Hemotórax en síndrome de Ehlers-Danlos tipo vascular

RESUMEN

El síndrome de Ehlers-Danlos de tipo vascular (SED IV) se trata de una rara alteración genética causada por una alteración del gen COL3A1 que codifica el colágeno tipo III. Este es el tipo de colágeno más frecuente en los vasos de mediano calibre y en algunos órganos como intestino y útero. Su alteración produce, entre otros, aneurismas y roturas de vasos y órganos. Para su diagnóstico se requiere de un alto nivel de sospecha clínica. Se trata de una enfermedad de manejo complejo que requiere de un equipo multidisciplinar para tratar las diferentes complicaciones que pueden acontecer.

Se presenta el caso de un paciente varón de 50 años diagnosticado de SED IV de forma incidental tras hemotórax secundario a acceso de tos.

© 2017 Elsevier España, S.L.U. y Sociedad Española de Reumatología y Colegio Mexicano de Reumatología. Todos los derechos reservados.

Palabras clave:

Síndrome de Ehlers-Danlos

SED IV

Síndrome de Ehlers-Danlos tipo vascular

Introduction

Type IV or vascular (EDS IV) Ehlers-Danlos syndrome is characterised by alterations in type III collagen metabolism by mutations of the COL3A1 gene. It usually starts at a young age with spontaneous ruptures of medium-calibre arteries. Its diagnosis requires a high level of suspicion in order to correctly direct the clinical history. Its management involves a series of measures to prevent trauma or risk situations. There is no effective pharmacological

treatment, only β -blockers have been tried to prevent catastrophic bleeding.

Clinical observation

We present the case of a 50-year-old male who was admitted to the pneumology department with a diagnosis of pneumonia associated with significant parapneumonic effusion; the patient reported prior symptoms of influenza, a coughing spell that triggered severe pain in the right haemothorax and presyncope symptoms.

Personal history of note included: smoker of 30 packs/year, hypertension under treatment, an episode of left carotid-cavernous fistula aged 25 treated by embolisation. At 37 years he presented with symptoms of sudden abdominal pain resulting in spontaneous

[☆] Please cite this article as: Álvarez K, López J, Hernández JA. Hemotórax en síndrome de Ehlers-Danlos tipo vascular. Reumatol Clin. 2019;15:e128–e129.

* Corresponding author.

E-mail address: kevalv@yahoo.es (K. Álvarez).

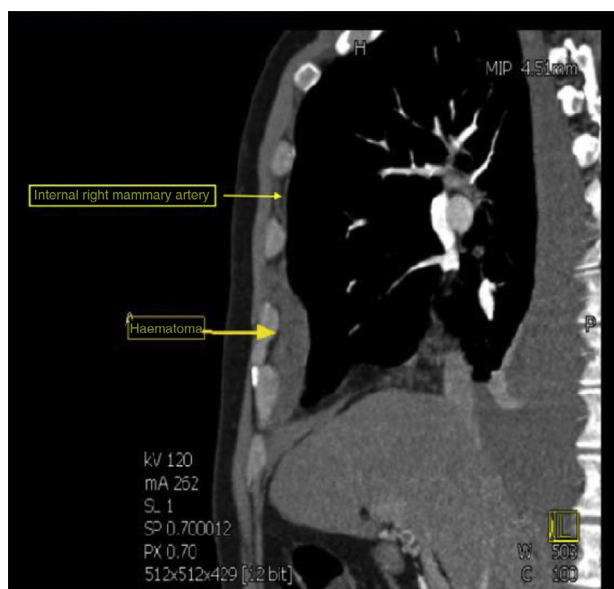


Fig. 1. CT image of the thorax, sagittal view. The internal mammary artery and the haematoma that originates from its rupture can be observed.

haemoperitoneum secondary to rupture of the round ligament, confirmed in emergency surgery. During the surgery, splenic rupture occurred which required splenectomy.

Family history of a father who died aged 30 years due to sudden death from an unexplained case. Paternal grandmother died aged 50 from internal bleeding secondary to a ruptured axillary artery from mild trauma.

On physical examination: cutis marmorata, abundant haematomas on the upper limbs and thorax, secondary to banal trauma, slight hyperlaxity in metacarpophalangeal joints, without typical facies.

Pleural drainage of dense haematic content was performed, after which a computed tomography (CT) of the thorax was performed which revealed the presence of a ruptured aneurysm of the right internal mammary artery, causing ipsilateral haemothorax (Fig. 1). He also had an aneurysm in the common hepatic artery. Embolisation of the ruptured aneurysm was performed as treatment.

When EDS is suspected, a confirmatory genetic study is carried out for the presence of heterozygosis in the splicing variant c.636+1G>T in gene COL3A1. The variant described is not recorded on the databases consulted, but similar variants in the same point that are associated with type IV EDS are. It is transmitted with autosomal dominant inheritance. Once the suspected diagnosis has been confirmed, the study is continued and the family is given genetic counselling, and treatment is started with β -blockers and controls in outpatient clinics. After one year of follow-up, the patient remains asymptomatic with no new bleeding episodes, and under treatment with β -blockers.

Discussion

EDS is a hereditary disease caused by mutations of the collagen gene with different subtypes.¹ EDS IV is the most severe form. It is inherited as an autosomal dominant trait and involves procollagen type III deficiency by mutation of the COL3A1 gene.² It

constitutes between 5% and 10% of all cases of EDS, with a prevalence of 1/50 000–1/200 000 inhabitants. It is a potentially fatal variant, increasing the risk of visceral and vascular rupture. The absence of hyperelasticity of large joints stands out, although the small distal joints of the hand may show moderate elasticity.³ Diagnosis is based on the sum of clinical criteria and is confirmed by genetic study.² There is no effective treatment, although the administration of β -blockers has been trialled previously to reduce catastrophic bleeding.^{4,5}

Follow-up includes minimising trauma, identifying patients and creating a care group around them, forming and facilitating individualised emergency plans, centralising treatment in referral centres, maintaining normal blood pressure and, in the event of high blood pressure, treating it strictly and monitoring the vascular tree by means of ultrasound, CT-arteriography or nuclear magnetic resonance on an annual basis.⁶

Conclusions

This is a rare disease, difficult to diagnose. With regard to genetic counselling and emergency management of the patient in the emergency department, it is advisable to know the different possible manifestations to reach a quick suspicion and avoid complications. It is important to avoid trauma, and diagnostic or therapeutic vascular techniques that are not strictly necessary.

Ethical disclosures

Protection of human and animal subjects. The authors declare that neither human nor animal testing has been carried out in this research.

Confidentiality of data. The authors declare that they have complied with their work centre protocols for the publication of patient data.

Right to privacy and informed consent. The authors declare that no patient data appear in this article

Conflict of interests

The authors have no conflict of interests to declare.

References

1. Pope FM, Narcisi P, Nicholls AC, Germain DP, Pals G, Richards AJ. COL3A1 mutations cause variable clinical phenotypes including acrogeria and vascular rupture. *Br J Dermatol.* 1996;135:163–81.
2. Pepin M, Schwarze U, Superti-Furga A, Byers PH. Clinical and genetic features of Ehlers-Danlos syndrome type IV, the vascular type. *N Engl J Med.* 2000;342:673–80.
3. Pepin MG, Byers PH. Ehlers-Danlos syndrome type IV. In: Pagon RA, Bird TD, Dolan CR, editors. *GeneReviews*. Seattle (WA): University of Washington, Seattle; 1993. Available from: <http://www.ncbi.nlm.nih.gov/books/NBK1494/?report=printable> [accessed 23.05.16].
4. Ong KT, Perdu J, de Backer J, Bozec E, Collignon P, Emmerich J, et al. Effect of celiprolol on prevention of cardiovascular events in vascular Ehlers-Danlos syndrome: a prospective randomised, open, blinded-endpoints trial. *Lancet.* 2010;376:1476–84.
5. Bergqvist D, Björck M, Wanhainen A. Treatment of vascular Ehlers-Danlos syndrome: a systematic review. *Ann Surg.* 2013;258:257–61.
6. Byers PH, Belmont J, Black J, de Backer J, Frank M, Jeunemaitre X, et al. Diagnosis, natural history and management in vascular Ehlers-Danlos syndrome. *Am J Med Genet Part C Semin Med Genet.* 2017;175:40–7.