




Sociedad Española  
de Reumatología -  
Colegio Mexicano  
de Reumatología

# Reumatología Clínica

www.reumatologiaclinica.org



## Case Report

### Laryngeal sarcoidosis in a child: Case report<sup>☆</sup>

Gabriel Vega-Cornejo,\* Priscila Ayala-Buenrostro

Clínica de Reumatología Pediátrica, Hospital México Americano, Guadalajara, Jalisco, Mexico



#### ARTICLE INFO

##### Article history:

Received 12 May 2017

Accepted 10 August 2017

Available online 19 September 2019

##### Keywords:

Sarcoidosis

Granuloma

Biopsy

#### ABSTRACT

Sarcoidosis is a chronic, multisystemic, granulomatous disorder. Our patient was a 2-year-old girl with multiple airway conditions and a partial response to inhaled and systemic steroids. She was positive for acute phase reactants and negative for antibodies. Polymerase chain reaction revealed atypical Mycobacteria and she was negative for Mycobacterium tuberculosis. Laryngeal sarcoidosis was diagnosed by histopathology in a biopsy of larynx that revealed a chronic granulomatous inflammatory process with Langhans giant cells and acute and ulcerated areas with changes compatible with tuberculosis. Treatment consisted of monthly gammaglobulin for 6 months at doses of 2 g/kg body weight, accompanied by Valmetrol<sup>TM</sup> and methotrexate. Immunomodulation with gammaglobulin was prescribed, with subsequent use of methotrexate-based immunosuppression. Currently, bronchoscopy shows no evidence of granulomas and she is negative for acute-phase reactants.

© 2017 Elsevier España, S.L.U. and Sociedad Española de Reumatología y Colegio Mexicano de Reumatología. All rights reserved.

### Sarcoidosis laríngea infantil: presentación de un caso clínico

#### RESUMEN

La sarcoidosis es un trastorno crónico, multisistémico y granulomatoso. Femenina de 2 años con múltiples cuadros de vías respiratorias, con esteroides inhalados y sistémicos presentando respuesta parcial, reactantes de fase aguda positivos, anticuerpos negativos, además de PCR de micobacterias atípicas con *Mycobacterium tuberculosis* negativa. Se diagnostica de sarcoidosis laríngea por histopatología biopsia de laringe con proceso inflamatorio crónico granulomatoso con células gigantes tipo Langhans, y áreas agudizadas y ulceradas con cambios compatibles con proceso fímico. Se inicia tratamiento con gammaglobulina mensual durante 6 meses a dosis de 2 g/kg/peso, Valmetrol<sup>®</sup> y metotrexate. Se decidió la inmunomodulación con gammaglobulina y con posterior uso de inmunosupresión a base de metotrexate. Actualmente broncoscopia sin evidencia de granulomas y reactantes de fase aguda negativos.

© 2017 Elsevier España, S.L.U. y Sociedad Española de Reumatología y Colegio Mexicano de Reumatología. Todos los derechos reservados.

##### Palabras clave:

Sarcoidosis

Granuloma

Biopsia

## Introduction

Sarcoidosis is a chronic, multisystemic and granulomatous disorder with an incidence of .22–.27 per 100,000 children per year. Involvement of the larynx is described less frequently, and represents .33%–2.1% of cases.<sup>1</sup>

<sup>☆</sup> Please cite this article as: Vega-Cornejo G, Ayala-Buenrostro P. Sarcoidosis laríngea infantil: presentación de un caso clínico. Reumatol Clin. 2019;15:e102–e104.

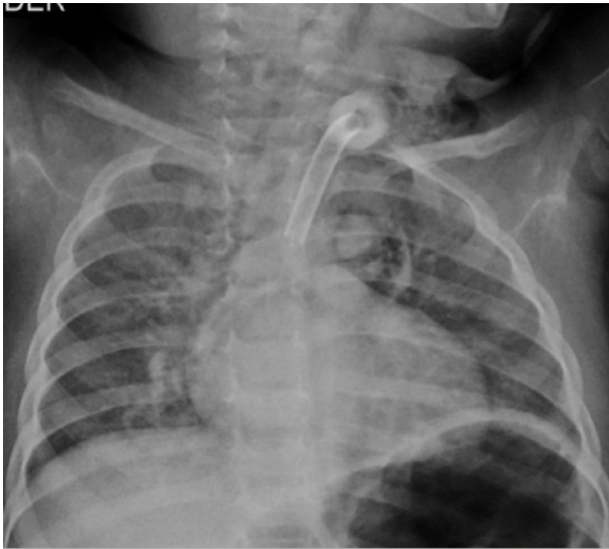\* Corresponding author.

E-mail addresses: [gvc81@hotmail.com](mailto:gvc81@hotmail.com), [info@creamx.com](mailto:info@creamx.com) (G. Vega-Cornejo).

Diagnosis is established by histological evidence of non-caseous granulomas in affected tissue, as well as exclusion of other granulomatous diseases such as tuberculosis, histoplasmosis, blastomycosis. It is characterised by the formation of non-necrotising epithelioid cell granulomas as a result of underlying immune deregulation, and there is typically multiorgan involvement.<sup>2</sup> Laryngeal sarcoidosis, a rare extrapulmonary manifestation of sarcoidosis, occurs infrequently as a complication of complete airway obstruction.<sup>3</sup> The estimated incidence of laryngeal involvement in patients with sarcoidosis ranges from 1% to 5%.<sup>4</sup> Initial clinical presentation includes fever, weight loss, fatigue, bone and joint pain, anaemia, hepatomegaly and lymphadenopathy.<sup>5</sup> In children under 5 years old, skin, eyes and joints are affected,

**Table 1**  
Laboratory results.

Studies undertaken	One month	3 months	6 months	9 months
Erythrocyte sedimentation rate	12 mm/h	63 mm/h	21 mm/h	6 mm/h
Polymerase chain reaction	0 mg/dl	.043 mg/dl	.098 mg/dl	.024 mg/dl
Antineutrophil cytoplasm antibodies Proteinase	Negative			Negative
Neutrophil perinuclear antibody Myeloperoxidase	Negative			Negative
Antinuclear antibody-HEp-2	Negative			Negative

**Fig. 1.** Plain chest X-ray with evidence of diffuse micronodular bilateral perihilar infiltrate.

whereas in older children, involvement of the lungs, lymph nodes and eyes predominates.<sup>6</sup> Several treatment modalities are reported for laryngeal sarcoidosis, including systemic corticosteroids, intralesional corticosteroid injection, and surgical removal.<sup>7</sup>

*Aim:* Presentation of a case of sarcoidosis in a child.

### Clinical observation

A 2-year-old female who started with viral croup, with multiple respiratory tract symptoms, under treatment with inhaled and systemic steroids with partial response.

No significant family history, incomplete vaccination schedule and no other pathological signs.

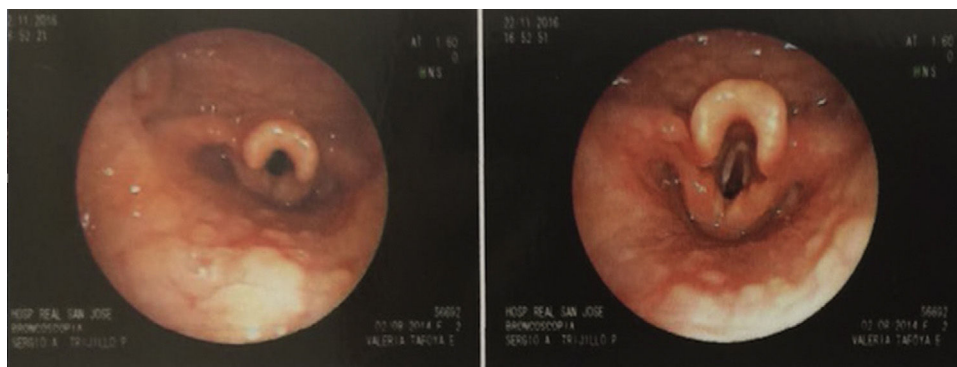
The diagnostic approach involves a search for infectious aetiology which might predispose to an inflammatory state. General laboratory data with normal parameters, acute phase reactants ESR maximum peak of 63 mm/h, negative antibodies in addition to PCR of atypical mycobacteria with negative *Mycobacterium tuberculosis* (Table 1) and chest X-ray (Fig. 1) are requested.

During the child's hospital stay she underwent endoscopy (Fig. 2) and laryngeal biopsy with histopathological report of chronic inflammatory granulomatous process with Langhans giant cells and acute and ulcerated areas with changes compatible with phymic process, resulting in a diagnosis of laryngeal sarcoidosis. Infectious granulomatous diseases, principally *Mycobacterium tuberculosis*, were ruled out by negative PCR. Management with monthly gamma globulin was initiated with doses of 2 g/kg body weight. Valmetrol® 3 tablets every 24 h.

Methotrexate at 15 mg/m<sup>2</sup>/SC weekly. Steroids were not used because the patient had been refractory since the onset of symptoms. Follow-up was offered with bronchoscopy with no evidence of negatively reacting granulomas. The patient continues with methotrexate management at 15 mg/m<sup>2</sup>/SC weekly, and folic acid 5 mg/24 h from Monday to Thursday.

### Discussion

Diagnosis is based on a compatible clinical and radiographic picture, supported by histological evidence of non-caseous granulomas in affected tissue, and ruling out other granulomatous diseases. The condition is characterised by the formation of granulomas as a result of underlying immune dysregulation, and there is typically multiorgan involvement. Although early childhood sarcoidosis is manifested by the triad of skin rash, arthritis and uveitis, there are different forms of presentation in children, like our case, with signs of pulmonary involvement. FDG-PET/CT can be used to assess inflammatory activity accurately in patients with persistent symptoms and without biological inflammatory activity, especially in rare locations or when biopsy is not possible.<sup>8</sup>

**Fig. 2.** Endoscopy showing multinodular oedematous laryngeal structures.

## Conclusions

In this patient in particular and due to her age, immunosuppression as referred to in different management protocols was not possible. In addition, she had failed to respond to high doses of steroids; therefore immunomodulation with gamma globulin and then immunosuppression based on methotrexate were decided to maintain control of her baseline disease.

## Ethical disclosures

**Protection of human and animal subjects.** The authors declare that neither human nor animal testing has been carried out under this research.

**Confidentiality of data.** The authors declare that they have complied with their work centre protocols for the publication of patient data.

**Right to privacy and informed consent.** The authors have obtained the informed consent of the patients and/or subjects referred to in the article. This document is held by the corresponding author.

## Conflict of interests

The authors have no conflict of interests to declare.

## References

1. Strychowsky JE, Vargas SO, Vielman R, Son MB, Rahbar R. Laryngeal sarcoidosis: presentation and management in the pediatric population. *Int J Pediatr Otorhinolaryngol.* 2015;79:1382–7.
2. Singh M, Kothur K. Pulmonary sarcoidosis masquerading as tuberculosis. *Indian Pediatr.* 2007;44:615–7.
3. Ryu C, Herzog EL, Pan H, Homer R, Gulati M. Upper airway obstruction requiring emergent tracheostomy secondary. *Am J Case Rep.* 2017;18:157–9.
4. van den Broek EM, Heijnen BJ, Verbist BM, Sjögren EV. Laryngeal sarcoidosis a case report presenting transglottic involvement. *J Voice.* 2013;27:647–9.
5. Shanthikumar S, Harrison J. Pulmonary sarcoidosis in a preschool patient. *Pediatr Pulmonol.* 2015;50:E41–3.
6. Mesa Álvarez A, Anes González G, Ruiz del Árbol Sánchez P. Sarcoidosis con afectación pulmonar y sistémica en una niña de 5 años. *Arch Bronconeumol.* 2011;47:52–3.
7. Tsubouchi K, Hamada N, Ijichi K, Umezaki T, Takayama K, Nakanishi Y. Spontaneous improvement of laryngeal sarcoidosis resistant to systemic corticosteroid administration. *Respirol Case Rep.* 2015;3:112–4.
8. Robin P, Benigni P, Feger B, Salaun PY, Abgral R. An atypical sarcoidosis involvement in FDG PET/CT: a case report. *Medicine (Baltimore).* 2016;95:e5700.