




Sociedad Española  
de Reumatología -  
Colegio Mexicano  
de Reumatología

# Reumatología Clínica

www.reumatologiaclinica.org



## Case report

# Treatment of Persistent Cutaneous Atrophy After Corticosteroid Injection With Fat Graft

Nádia Martins<sup>a,b,\*</sup>, Joaquim Polido-Pereira<sup>a</sup>, Manuel Caneira<sup>c</sup>, João Eurico Fonseca<sup>a</sup>

<sup>a</sup> Rheumatology and Metabolic Bone Diseases Department, Hospital de Santa Maria, CHLN, Lisbon, Portugal

<sup>b</sup> Rheumatology Department, Hospital de São Teotónio, CHTV, Viseu, Portugal

<sup>c</sup> Plastic Surgery Department, Hospital de Santa Maria, CHLN, Lisbon, Portugal

## ARTICLE INFO

### Article history:

Received 18 July 2017

Accepted 8 September 2017

### Keywords:

Fat graft  
Subcutaneous fat atrophy  
Hypopigmentation  
Corticosteroid injections

## ABSTRACT

Subcutaneous fat atrophy and hypopigmentation are potential adverse side effects of local corticosteroid injection that may resolve spontaneously within 1–2 years. This report shows that fat grafting provides a simple, effective and safe correction of corticosteroid induced cutaneous atrophy with very satisfying esthetic and functional results.

© 2017 Elsevier España, S.L.U. and Sociedad Española de Reumatología y Colegio Mexicano de Reumatología. All rights reserved.

## Tratamiento de la atrofia e hipopigmentación cutánea secundaria a infiltración de corticosteroides con injerto de grasa

## RESUMEN

La atrofia de la grasa subcutánea y la despigmentación de la piel son efectos secundarios adversos potenciales de la inyección local de corticosteroides que pueden resolverse espontáneamente en 1-2 años. Este caso muestra que el injerto de grasa proporciona una corrección simple, eficaz y segura de estas complicaciones con resultados estéticos y funcionales muy satisfactorios.

© 2017 Elsevier España, S.L.U. y Sociedad Española de Reumatología y Colegio Mexicano de Reumatología. Todos los derechos reservados.

### Palabras clave:

Injerto de grasa  
Atrofia de la grasa subcutánea  
Hipopigmentación  
Inyecciones de corticosteroides

## Introduction

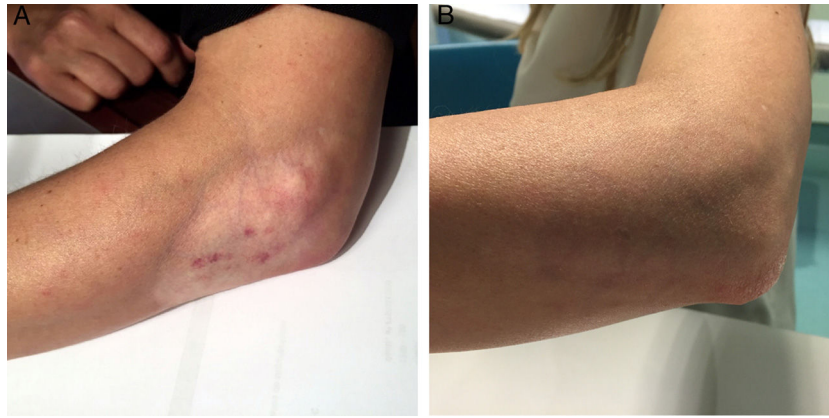Corticosteroid injections are usually simple and safe procedures, used in rheumatology clinical practice.<sup>1</sup> A number of complications can arise when performing procedures involving joints and soft tissues. As expected, the most frequent are minor complications. These can occur with the aqueous solution or the crystalloid suspension form, employed to confer them a longer-lasting effect.<sup>2,3</sup> Skin hypopigmentation has been reported to occur in 1.3%–6% of patients who underwent local corticosteroid

injection.<sup>2,4</sup> It generally occurs 1–4 months after injection and takes 6–30 months to resolve.<sup>1</sup> Subcutaneous fat atrophy after local injection of corticosteroids has an estimated incidence that varies from 1.5 to 40%.<sup>5–10</sup>

In most cases, these two complications are self limited but may last 6 to 24 months.<sup>11</sup> Rare cases have been described where no spontaneous improvement occurs, in which surgical treatment should be considered. In these refractory cases, fat injection, temporal fascia implantation and normal saline infiltration are reported as treatment options.<sup>11,12</sup>

\* Corresponding author.

E-mail address: [nadia.filipaem@hotmail.com](mailto:nadia.filipaem@hotmail.com) (N. Martins).



**Fig. 1.** (A) Skin hypopigmentation and subcutaneous fat atrophy in the right elbow of the patient after corticosteroid injections; (B) elbow surface 24 months after fat graft.

### Case Report

We report the case of a 47 years old female with Systemic Lupus Erythematosus, treated with prednisolone 5 mg *id* and methotrexate 15 mg/week.

Because of right elbow articular inflammatory complaints, 2 corticosteroid injections without anesthetic were performed, one of which was a periarticular epicondylar infiltration with 40 mg of methylprednisolone and the other one an intra-articular injection with 40 mg triamcinolone hexacetonide.

Within weeks, skin hypopigmentation and subcutaneous fat atrophy were observed in the site of the injections (Fig. 1). Two years later she was referred to a plastic and reconstructive surgery consultation because there were no signs of improvements. Twenty-five cc of fat harvested from the flanks per wet technique using low-pressure aspiration and processed by decantation, were injected in the arm defect. The improvement of the skin atrophy was almost immediate after the fat graft. The repigmentation occurred later and gradually. At 24 month follow-up consultation, the patient demonstrated almost full restoration of the elbow surface with a stabilized graft (Fig. 1).

### Discussion

Subcutaneous fat atrophy and hypopigmentation are potential adverse side effects of local corticosteroid injection. Superficial atrophy of the skin and adipose tissue is caused in most cases by crystal deposition outside the intended target injection site, and less commonly by partial backward flow of the injected fluid. The mechanism for these skin changes involves combination of factors such as: an inhibitory effect on fibroblasts, an excessive collagenase activation, the blockage of lymphatic pathways and the reduction of melanocyte function, leading to hypopigmentation. In about half of all cases, the affected area returns to normal over a few months and the duration of this process seems to be a function of the corticosteroid dose.<sup>1,12</sup> In order to minimize subcutaneous fat atrophy and hypopigmentation, steroids with shorter half lives, and adequate solubility and potency to the target site must be used. Therefore, steroids with low solubility, such as triamcinolone acetonide, are preferably injected into joints, whereas steroids with high solubility are preferably injected into soft tissues. Of note, methylprednisolone is less associated with these adverse effects than is triamcinolone and, therefore, may be the preferred preparation when injecting superficial structures.<sup>13</sup> However, and despite all the preventive measures, complications may still occur.

Local injection of saline solution has been proposed as a treatment for steroid induced cutaneous atrophy. The proposed mechanism is that the saline solution re-dissolve the steroid

crystals present in the tissues of patients with this complication.<sup>14</sup> However, multiple injections are often required until satisfactory results are obtained.<sup>14</sup> Injection of fat has been shown to be more helpful in the treatment of subcutaneous atrophy caused by steroid injection. The cutaneous defect improves dramatically after fat grafting as evidenced in our case and by other authors.<sup>11,12</sup> It is postulated that adipose-derived stem cells can be responsible for this changes.<sup>15</sup> The increase of vasculogenesis induced by the grafted fat is another proposed mechanism.<sup>16</sup>

### Conclusion

This report shows that fat graft provides a simple, effective and safe correction of corticosteroid induced cutaneous atrophy with very satisfying esthetic and functional results.

### Ethical Disclosures

**Protection of human and animal subjects.** The authors declare that no experiments were performed on humans or animals for this study.

**Confidentiality of data.** The authors declare that they have followed the protocols of their work center on the publication of patient data.

**Right to privacy and informed consent.** The authors have obtained the written informed consent of the patients or subjects mentioned in the article. The corresponding author is in possession of this document.

### Conflict of Interest

I declare no conflict of interest.

### References

- Holland C, Jaeger L, Smentkowski U, Weber B, Otto C. Septic and aseptic complications of corticosteroid injections. *Dtsch Arztebl Int.* 2012;109:425–30.
- Brinks A, Koes BW, Volkers ACW, Verhaar JAN, Bierma-Zeinstra SMA. Adverse effects of extra-articular corticosteroid injections: a systematic review. *BMC Musculoskelet Disord.* 2010;11:206.
- Inês LP, da Silva JA. Soft tissue injections. *Best Pract Res Clin Rheumatol.* 2005;19:503–27.
- Papadopoulos PJ, Edison JD. The clinical picture – soft tissue atrophy after corticosteroid injection. *Cleve Clin J Med.* 2009;76:373–4.
- Ayres S Jr. Alopecia areata with associated subcutaneous atrophy. *Arch Dermatol.* 1964;90:242.
- Bisset L, Beller E, Jull G, Brooks P, Darnell R, Vicenzino B. Mobilisation with movement and exercise, corticosteroid injection, or wait and see for tennis elbow: randomised trial. *BMJ.* 2006;333:939.

7. Tonks JH, Pai SK, Murali SR. Steroid injection therapy is the best conservative treatment for lateral epicondylitis: a prospective randomised controlled trial. *Int J Clin Pract.* 2007;61:240–6.
8. Hay EM, Paterson SM, Lewis M, Hosie G, Croft P. Pragmatic randomised controlled trial of local corticosteroid injection and naproxen for treatment of lateral epicondylitis of elbow in primary care. *BMJ.* 1999;319:964–8.
9. Price R, Sinclair H, Heinrich I, Gibson T. Local injection treatment of tennis elbow – hydrocortisone, triamcinolone and lignocaine compared. *Br J Rheumatol.* 1991;30:39–44.
10. Nichols AW. Complications associated with the use of corticosteroids in the treatment of athletic injuries. *Clin J Sport Med.* 2005;15:370–5.
11. Imagawa K, Ohkuma S. A case of fat injection for treating subcutaneous atrophy caused by local administration of corticosteroid. *Tokai J Exp Clin Med.* 2010;35:66–9.
12. Stokes RB. Treatment of steroid induced lipoatrophy with structural fat grafting. *Mod Plast Surg.* 2012;2:5–7.
13. MacMahon PJ, Eustace SJ, Kavanagh EC. Injectable corticosteroid and local anesthetic preparations: a review for radiologists. *Radiology.* 2009;252:647–61.
14. Shumaker PR, Rao J, Goldman MP. Treatment of local, persistent cutaneous atrophy following corticosteroid injection with normal saline infiltration. *Dermatol Surg.* 2005;10:1340–3.
15. Rigotti G, Marchi A, Galie M, Baroni G, Benati D, Krampera M, et al. Clinical treatment of radiotherapy tissue damages by lipoaspirates transplant: a healing process mediated by adipose derived stem cells. *Plast Reconstr Surg.* 2007;119:1409–22.
16. Suga H, Glotzbach JP, Sorkin M, Longaker MT, Gurtner GC. Paracrine mechanism of angiogenesis in adipose-derived stem cell transplantation. *Ann Plast Surg.* 2014;72:234–41.