



Sociedad Española
de Reumatología -
Colegio Mexicano
de Reumatología

Reumatología Clínica

www.reumatologiaclinica.org



Clinical Case

Pulmonary-renal syndrome secondary to cocaine-levamisole-induced vasculitis: A case report[☆]

Mauricio Restrepo-Escobar,^{a,b,*} Dayana Sylva,^c Juan Guillermo Gamboa,^{b,d} Andrés Echeverri,^a Javier Márquez,^a Luis Fernando Pinto^a

^a Sección de Reumatología, Hospital Pablo Tobón Uribe, Medellín, Colombia

^b Facultad de Medicina, Universidad de Antioquia, Medellín, Colombia

^c Facultad de Medicina, Universidad Pontificia Bolivariana, Medellín, Colombia

^d Sección de Medicina Interna, Hospital Pablo Tobón Uribe, Medellín, Colombia

ARTICLE INFO

Article history:

Received 29 December 2017

Accepted 20 February 2018

Keywords:

Vasculitis

Cocaine

Levamisole

Alveolar hemorrhage

Pulmonary-renal syndrome

ABSTRACT

Pulmonary-renal syndrome has rarely been reported as the clinical presentation of vasculitis caused by the consumption of cocaine adulterated with levamisole. We report the case of a patient in whom we detected the clinical manifestations and indicate the difficulties that arose in relation to the diagnostic and therapeutic approach.

© 2018 Elsevier España, S.L.U. and Sociedad Española de Reumatología y Colegio Mexicano de Reumatología. This is an open access article under the CC BY-NC-ND license (<http://creativecommons.org/licenses/by-nc-nd/4.0/>).

Palabras clave:

Vasculitis

Cocaína

Levamisol

Hemorragia alveolar

Síndrome pulmón-riñón

Síndrome pulmón-riñón secundario a vasculitis por cocaína/levamisol: reporte de caso

RESUMEN

El síndrome pulmón-riñón rara vez ha sido reportado como cuadro clínico de presentación de vasculitis causada por el consumo de cocaína contaminada con levamisol. Se reporta el caso de un paciente con este cuadro clínico y se señalan las dificultades que se presentaron durante el abordaje diagnóstico y terapéutico.

© 2018 Elsevier España, S.L.U. and Sociedad Española de Reumatología y Colegio Mexicano de Reumatología. Este es un artículo Open Access bajo la licencia CC BY-NC-ND (<http://creativecommons.org/licenses/by-nc-nd/4.0/>).

Introduction

Cocaine consumption is still a public health problem. The adulteration of cocaine with substances such as levamisole leads to the appearance of additional medical problems. Vasculitis caused by levamisole is highly heterogeneous in terms of clinical symptoms and analytical results, hindering diagnosis.

Clinical observation

A 34 year-old male with a history of reactive arthritis and daily marihuana consumption. He denied consuming cocaine. He was admitted for one week due to general discomfort, pallor, a dry cough, thoracic pain and dyspnea. Mucocutaneous pallor, hypoxemia and rale in the base of the lungs. He was normotensive, with no tachycardia or fever.

He had severe anaemia, renal dysfunction and mixed opacities in both pulmonary fields (Fig. 1 and Table 1). He was diagnosed pulmonary-renal syndrome and treatment commenced with high doses of steroids and blood cell transfusion. At first the diagnosis of systemic lupus erythematous (SLE) was considered due to the finding of hypocomplementemia. Additional studies

[☆] Please cite this article as: Restrepo-Escobar M, Sylva D, Gamboa JG, Echeverri A, Márquez J, Pinto LF. Síndrome pulmón-riñón secundario a vasculitis por cocaína/levamisol: reporte de caso. 2020;16:239–241.

* Corresponding author.

E-mail address: mauricio.restrepo@udea.edu.co (M. Restrepo-Escobar).

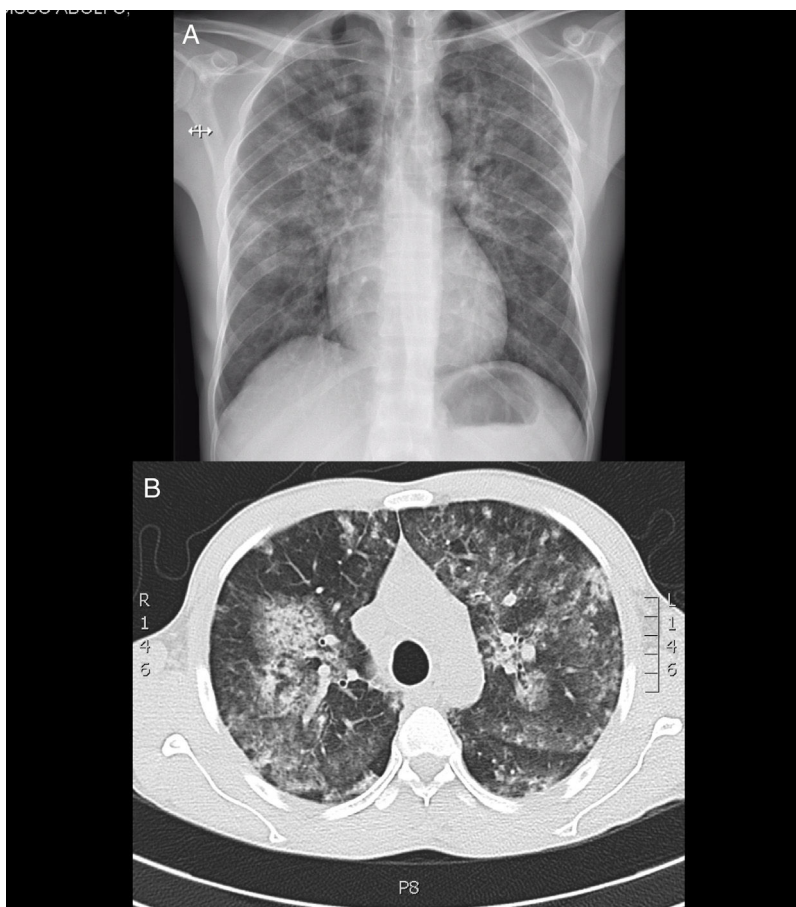


Figure 1. A) Thoracic X-ray showing diffuse infiltrates in both pulmonary fields. B) Generalised mixed opacities observed in high resolution thoracic tomography.

found multiple antibody positivity: ANCA (antimyeloperoxidase and antiproteinase-3), ANA, anti-Ro, anti-La, lupus anticoagulant, rheumatoid factor and anticardiolipin IgM. Anti-Sm, anti-DNA and anti-basement glomerular membrane antibodies were negative.

Diffuse endocapilar glomerulonephritis was observed in a renal biopsy, with immune complex deposits and tubulointerstitial nephritis. Fibrobroncoscopy confirmed alveolar haemorrhage (haemosiderophages 40%) and ruled out infection. During a subsequent evaluation perforation of the nasal septum was observed and the patient confirmed frequent consumption of cocaine. As well as insisting on the cessation of consumption treatment with prednisolone continued, with good clinical response and a rise in haemoglobin, although there was only partial improvement in renal function, so that additional monthly boli of cyclophosphamide were added.

Discussion

During recent years the number of cases of vasculitis associated with levamisole-adulterated cocaine consumption has increased. This disease may compromise multiple organs and systems.^{1,2}

Alveolar haemorrhage is rare. McGrath et al. described a series of 30 cases of levamisole-induced ANCA vasculitis. Three of the cases had alveolar haemorrhage, and it was not possible to prove renal involvement in any of them.³ Cases of pulmonary-renal syndrome are even rarer due to this entity.⁴

No definitive criteria for diagnosis of this syndrome exist. Diagnosis is based on epidemiological, clinical and analytical findings. In the majority of cases it is not possible to prove contamination by levamisole, as the test is not clinically available and measurement has to take place within 24 hrs. of the previous consumption. A high level of suspicion is necessary prior to probing for cocaine consumption. Differential diagnosis is broad. It may be confused with vasculitis associated with ANCA, Goodpasture syndrome and even SLE.

Vasculopathy secondary to levamisole is characterised by high titers of p-ANCA directed against multiple rare antigens, as well as concomitant positivity for c-ANCA,^{5,6} a rare expression in patients with primary vasculitis. Positivity for multiple antibodies and consumption as a complement may lead to confusion with SLE.

The rate of recurrence in the case of continued cocaine consumption is high. The role of immunosuppressor therapy is unknown, and no treatment patterns have been defined. The patient responded partially to steroids and the suspension of the causal agent. The addition of cyclophosphamide seems to have contributed to his final clinical improvement.

Conclusions

This case represents a clinical challenge due to its atypical form of presentation, the severity of its manifestations and the difficulty of diagnosis. It is necessary to know the different clinical and analytical manifestations caused by cocaine/levamisole consumption,

Table 1
Analytical results.

Analysis	Result
Creatinine (0.60-1.10 mg/dl)	2.16
Urine analysis (cells per high power field (HPF))	Proteins 75 mg/leukocytes 0- 5/CAP/erythrocytes 21-50/HPF (70% crenated)
Proteins in urine 24 hrs (10-150 mg)	1,410
C Reactive protein (0.01-0.82 mg/dl)	4.13
Haemoglobin (13.0-17.0 g/dl)	3.1
Haematocrit (42.0-52.0%)	10.1
White cells (4,500-11,000/mm ³)	8,100
Neutrophils (1,500-6,100/mm ³)	2,800
Lymphocytes (1,500-3,500/mm ³)	4,800
Eosinophils (0-700/mm ³)	100
Monocytes (0-1,000/mm ³)	400
Basophils (0-200/mm ³)	0
Platelets (150-450 × 10 ³ /mm ³)	315,000
Ferritin (15-200 ng/ml)	70
Vitamin B ₁₂ (124-732 pg/ml)	492
Folic acid (3.5-19.5 ng/ml)	10.3
Complement C3 (82-185 mg/dl)	75
Complement C4 (15-53 mg/dl)	9.9
ANA (dilution, pattern)	1:640, spotted
Anti-Ro (0-20 units)	118.6
Anti-La (0-20 units)	87.6
Anti-Sm (0-20 units)	4.4
Anti-RNP (0-20 units)	5.3
Native anti-DNA	Negative
Anticardiolipins IgM (0-12.5 MPL/ml)	29.5
Anticardiolipins IgG (0-15 GPL/ml)	2.9
Confirmatory lupus anticoagulant	Normalised ratio 1.72 (positive)
Anti-β ₂ glycoprotein 1 IgG (0-20 units)	.70
Anti-β ₂ glycoprotein 1 IgM (0-20 units)	6.19
ANCA Anti MPO (0-20 units)	105.5
ANCA Anti PR3 (0-20 units)	48.7
Anti-glomerular basement membrane IgG (0-20 units)	3.6
Rheumatoid factor (0-30 UI/ml)	40.6
Prothrombin time (s)	11.2
Partial thromboplastin time (s)	31.6

and to maintain a high level of suspicion regarding the possibility of this consumption, which may be denied by the patient.

Conflict of interests

The authors have no conflict of interests to declare.

References

- Espinoza LR, Perez AR. Cocaine-induced vasculitis: Clinical and immunological spectrum. *Curr Rheumatol Rep.* 2012;14:532–8.
- Marquez J, Aguirre L, Muñoz C, Echeverri A, Restrepo M, Pinto LF. Cocaine-Levamisole-Induced Vasculitis/Vasculopathy Syndrome. *Curr Rheumatol Rep.* 2017;19:36.
- McGrath MM, Isakova T, Rennke HG, Mottola AM, Laliberte KA, Niles JL. Contaminated Cocaine and Antineutrophil Cytoplasmic Antibody-Associated Disease. *Clin J Am Soc Nephrol.* 2011;6:2799–805.
- Carlson AQ, Tuot DS, Jen KY, Butcher B, Graf J, Sam R, et al. Pauci-immune glomerulonephritis in individuals with disease associated with levamisole-adulterated cocaine: A series of 4 cases. *Medicine (Baltimore).* 2014;93:290–7.
- Trimarchi M, Bussi M, Sinico RA, Meroni P, Specks U. Cocaine-induced midline destructive lesions—an autoimmune disease? *Autoimmun Rev.* 2013;12:496–500.
- Nolan AL, Jen KY. Pathologic manifestations of levamisole-adulterated cocaine exposure. *Diagn Pathol.* 2015;10:48.