



Sociedad Española
de Reumatología -
Colegio Mexicano
de Reumatología



Letter to the Editor

Non-thermal atmospheric plasma generated with helium gas as a promoter of wound healing by salivary gland biopsy in Sjögren's syndrome. Presentation two cases[☆]



Plasma atmosférico no-térmico generado con gas helio como promotor de la cicatrización de herida por biopsia de glándulas salivales en el síndrome de Sjögren. Presentación de dos casos

Dear Editor,

Sjögren's syndrome (SS) is an autoimmune disease characterised by the destruction of exocrine glands.¹ Its diagnosis is based on several characteristics, of which focal lymphocytic sialadenitis seen on minor salivary gland biopsy (MSGB) is the criterion with the highest specificity and sensitivity for diagnosis.¹⁻³ Stitches are placed⁴ for 7 days following the biopsy. During this period, they can cause tissue tension, pain, accumulation of microorganisms and chronic inflammation.⁵

In physics, ionising a gas produces the fourth state of matter, known as plasma, which can be generated non-thermally at atmospheric pressure (NTAP). There are reports showing a reduction in wound repair time using NTAP generated with helium gas.^{6,7} To generate NTAP, a coaxial needle reactor configuration is used: the nozzle has a radius of 1 mm containing a copper inner electrode coated with a ceramic, and the outer electrode is made of stain-

less steel. The NTAP is produced by a radiofrequency generator at 13.56 MHz and helium is the gas used, at a flow rate of. 5lpm.

We present the cases of two patients with clinical criteria of SS, females aged 51 and 76 years, with hyposalivation that restricted oral functions. Both underwent MSGB⁴ under informed consent, and instead of suturing, two applications of 3 min each of NTAP were performed at 5 mm from the wound (Fig. 1).

Case 1. Reported asymptomatic one hour after application of NTAP and showed wound repair at 2 days. Case 2. Reported asymptomatic 24 h after NTAP application and showed wound repair at 3 days.

Due to the complications that can arise from sutures, several authors have conducted research on means to replace suturing. One study that performed oral surgeries using laser diode to promote healing, saw tissue repair 10 days after the surgical procedures,⁸ while in the two reported cases the MSGB wounds healed rapidly using NTAP. With wound healing in less than 3 days, post-surgical complications such as infection and wound dehiscence, which are more common in patients with hyposalivation because of decreased salivary flow, were avoided.⁵ Sensitivity changes at the biopsy site are reported by many patients. In one study, symptoms following parotid and labial mucosal MSGB were assessed, and for the latter patients reported changes in sensitivity at the post-surgical site that lasted between one week and 6 months.⁹ The patients reported here were asymptomatic in under 24 h, recovering tissue function during this period. The follow-up of the

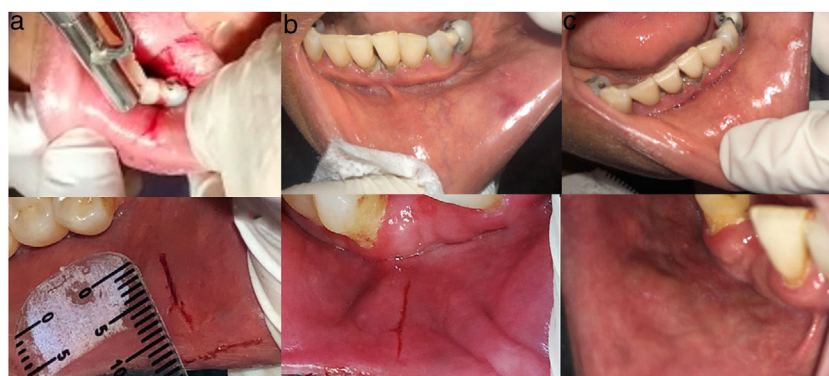


Fig. 1. Cases that underwent MSGB. Case 1: 1a) Surgical incision and initial application of NTAP. 1b) Incision in the process of repair after the two applications of NTAP (1 h after taking the biopsy). 1c) Labial mucosa in the biopsy site, regenerated after two days. Case 2: 2a) Surgical incision. 2b) Incision in the process of repair after the two applications of NTAP (1 h after the biopsy). 2c) Labial mucosa regenerated after 3 days following the biopsy.

[☆] Please cite this article as: Ibáñez-Mancera NG, Toral-Rizo VH, Lara-Carrillo E, López-Callejas R. Plasma atmosférico no-térmico generado con gas helio como promotor de la cicatrización de herida por biopsia de glándulas salivales en el síndrome de Sjögren. Presentación de dos casos. Reumatol Clin. 2022;18:439–440.

patients included an exploration of the biopsy site, identifying that it recovered normal characteristics; this may be the result of NTAP application, as it releases free radicals that stimulate angiogenesis and fibroblasts, resulting in an organised tissue repair process.^{6,7,10}

In conclusion, with the cases presented, NTAP proved a useful and safe alternative for patients, as tissue regeneration was observed within 72 h following the biopsy, thus avoiding postoperative complications.

References

- Caraba A, Babalic FC, Iurciuc S, Iurciuc M. The utility of major salivary gland ultrasonographic parameters in the Diagnosis of Sjögren Syndrome. *Dis Markers*. 2019;2019:1716848, <http://dx.doi.org/10.1155/2019/1716848>.
- Chiu Y-H, Lee T, Chao E, Chen I-F, F-Ch Liu, et al. Application of classification criteria of Sjogren syndrome in patients with sicca symptoms: real-world experience at a medical center. *J Formosan Med Assoc*. 2019;119:480–7, <http://dx.doi.org/10.1016/j.jfma.2019.06.012>.
- Lacombre V, Lacout C, Lozac'h P, Ghali A, Gury A, et al. Unstimulated whole saliva flow for diagnosis of primary Sjögren's syndrome: time to revisit the threshold? *Arthritis Res Ther*. 2020;22:38, <http://dx.doi.org/10.1186/s13075-020-2132-3>.
- Trevisani VFM, Posoto SG, Fernandes M, Lopes M, Fialho S. Recommendations from the Brazilian society of rheumatology for the diagnosis of Sjögren's syndrome (Part I): glandular manifestations (systematic review). *Adv Rheumatol*. 2019;59:58, <http://dx.doi.org/10.1186/s42358-019-0102-8>.
- Vinke J, Kaper HJ, Vissink A, Sharma PK. Dry mouth: saliva substitutes which adsorb and modify existing salivary condition films improve oral lubrication. *Clin Oral Invest*. 2020, <http://dx.doi.org/10.1007/s00784-020-03272-x>.
- López-Callejas R, Peña-Eguiluz R, Valencia-Alvarado R, Mercado-Cabrera A, Rodríguez-Méndez BG, et al. Alternative method for healing the dia-

betic foot by means of a plasma needle. *Clin Plasma Med*. 2018;9:19–23, <http://dx.doi.org/10.1016/j.cpm.2018.01.001>.

- Betancourt-Ángeles M, Peña-Eguiluz R, López-Callejas R, Domínguez-Cadena NA, Mercado-Cabrera A, et al. Treatment in the healing of burns with a cold plasma source. *Int J Burn Trauma*. 2017;7:142–6. PMID: 29348977; PMCID: PMC5768930.
- Derikvand N, Chinipardaz Z, Ghasemi S, Chiniforush N. The versatility of 980 nm Diode laser in dentistry: a case series. *J Lasers Med Sci*. 2016;7:205–8, <http://dx.doi.org/10.15171/jlms.2016.36>.
- Delli K, Dagal EF, Bootmas H, Vissink A, Spijkervet FK. Patient-reported change of sensibility and pain after parotid and labial gland biopsy applied for primary Sjögren' syndrome diagnostics: one-year follow-up study. *Clin Exp Rheumatol*. 2018;112 36 Suppl:S173–6. PMID: 30156543.
- Brun P, Pathak S, Castagliuolo I, Palú G, Brun P, Zuin M, et al. Helium generated cold plasma finely regulates activation of human fibroblast-like primary cells. *PLoS One*. 2014;9, <http://dx.doi.org/10.1371/journal.pone.0104397>.

Norma Guadalupe Ibáñez-Mancera,^{a,b,*} Víctor Hugo Toral-Rizo,^a Edith Lara-Carrillo,^a Régulo López-Callejas^c

^a *Clínica Orocentro, Facultad de Odontología, UAEMex, Toluca de Lerdo, Mexico*

^b *CICS-UST del Instituto Politécnico Nacional, Mexico City, Mexico*

^c *Plasma Physics Laboratory, Instituto Nacional de Investigaciones Nucleares, Ocoyoacac, Mexico*

* Corresponding author.

E-mail address: nibanezm951@profesor.uaemex.mx (N.G. Ibáñez-Mancera).

<https://doi.org/10.1016/j.reumae.2021.04.002>

2173-5743/ © 2021 Elsevier España, S.L.U. and Sociedad Española de Reumatología y Colegio Mexicano de Reumatología. All rights reserved.

Answer to the Letter to the Editor: Methotrexate in interstitial lung disease associated with rheumatoid arthritis[☆]



Respuesta a la carta al editor: Metotrexato en la neumopatía intersticial asociada a la artritis reumatoide

Dear Editor,

We appreciate the interest shown by Arboleya-Rodríguez¹ in our original: "Systematic Review of the Impact of Drugs on Diffuse Interstitial Lung Disease Associated with Rheumatoid Arthritis (RA-DILD)"² and his critical comment on one of the conclusions given in our article: "It is not necessary to discontinue methotrexate (MTX) in patients with RA-DILD, as there is evidence that it does not increase the incidence or exacerbations of DILD and improves survival".

We did not include acute MTX pneumonitis (idiosyncratic hypersensitivity reaction) in our PICO question². We believe that it cannot be claimed that RA-associated DILD predisposes to the development of acute MTX pneumonitis based on a single retrospective study conducted in the 1980s³. We emphasise the value of systematic reviews (SR) rather than individual studies to search for evidence that is useful for clinical practice. The evidence found in our SR² indicates that MTX does not increase either the incidence or exacerbations of RA-DILD.

The aim of treatment should be to control RA without worsening the course of the DILD. When MTX is part of the treatment,

the decision to continue or discontinue it should be tailored to the individual patient. However, there is growing evidence that rather than being discontinued, MTX has an important role to play in the treatment of patients with RA-DILD^{2,4-6}.

Of the other two articles mentioned by Arboleya to advise discontinuing MTX in patients with RA and DILD, one is a retrospective study⁷, without a control group, of a single-centre case series that was included in our SR², and our analysis can be found there. The other is the CIRT trial⁸ (published after our SR²), conducted in patients with cardiovascular disease and metabolic syndrome or diabetes to investigate the side effects of MTX versus placebo. Patients with systemic rheumatic diseases and/or interstitial lung disorders were excluded from this clinical trial. They found episodes consistent with acute pneumonitis in six of the 3291 patients allocated to MTX and one of the 2080 allocated to placebo (HR 6.94 [95% CI .85–56.0]), but in no case was this considered likely or definitive on adjudication. Therefore, no conclusions can be drawn from this study on the performance of MTX in RA-DILD.

In conclusion, we believe that it is very important to control the inflammatory activity of RA without worsening the progression of DILD. When these patients need biological therapy, abatacept or rituximab is preferable to anti-TNF (with more potential risk) or targeted synthetic disease-modifying antirheumatic drugs (DMARDs), given the lack of evidence. Treatment should always be individualised. In this context, it does not seem necessary to discontinue MTX in patients with RA-DILD, as there is evidence that it increases neither the incidence nor exacerbations of RA-DILD and it improves survival.

References

[☆] Please cite this article as: Carrasco Cubero C, Chamizo Carmona E. Respuesta a la carta al editor: Metotrexato en la neumopatía intersticial asociada a la artritis reumatoide. *Reumatol Clin*. 2022;18:440–441.