

## Images in Clinical Rheumatology

### Antiphospholipid syndrome: A recurrent cardiac thromboembolic insult in spite of optimal anticoagulation



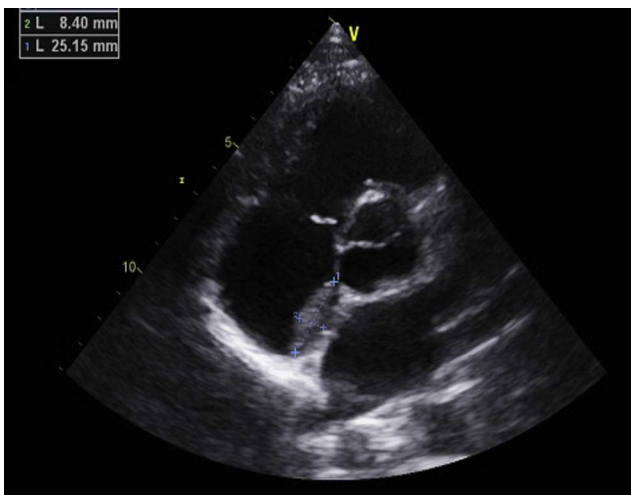
### Síndrome antifosfolípido: lesión tromboembólica cardiaca recurrente a pesar de anticoagulación óptima

André Viveiros Monteiro\*, Luísa Moura Branco, Lídia de Sousa, Rui Cruz Ferreira

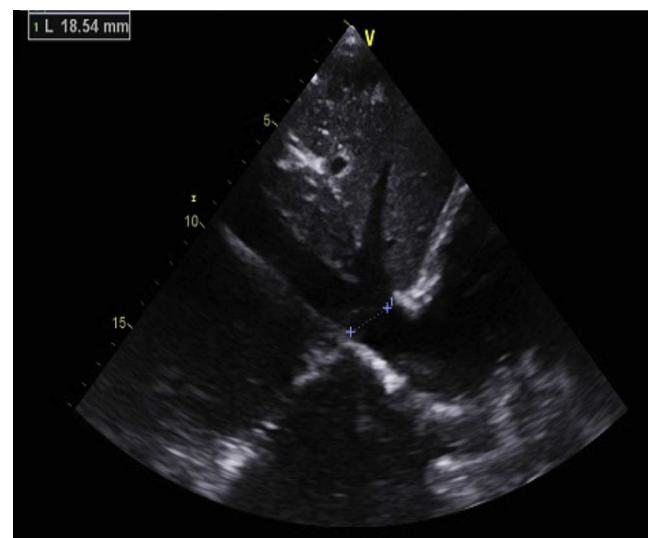
Cardiology Department, Hospital of Santa Marta, Lisbon, Portugal

Antiphospholipid syndrome (APS) is an autoimmune disease, with antiphospholipid antibodies associated with hypercoagulability, vascular thrombosis, and fetal loss.<sup>1,2</sup> Cardiac involvement occurs frequently, and is deeply related to hypercoagulability in spite of recommended anticoagulant therapy.<sup>3</sup> In this report, we describe the images of a Caucasian 19-year-old male, with a previous history, 4 years earlier, of an acute in situ right chamber thromboembolic episode submitted to a surgical intracardiac thrombectomy. At this time APS was diagnosed with increased levels of lupus anticoagulant and IgM anti-beta(2)-glycoprotein I. All other autoantibodies were negative. He was readmitted in April 2012 with an initial suspicion of endocarditis. Intracardiac and

inferior vena cava thrombi as well as acute and chronic pulmonary thromboembolism were detected in spite of adequate anticoagulation. After full dose anticoagulation he improved well and was discharged. In September 2012 he was readmitted after 2 weeks of fever, dyspnea and left thoracic pain again with pulmonary thromboembolism. Transthoracic echocardiogram (TTE) revealed an image suggestive of a thrombus at the upper part of the atrial septum in the right atrium (25 × 8 mm), **Image 1**, and in the inferior vena cava (18 mm) near the roof of the right atrium, **Image 2**. Also in the infundibulum of the right ventricle and in the right ventricular outflow tract several freely moving masses were visualized, indicative of thrombus near the lateral wall, **Image 3**. A long course of antibiotic was done and all microbiological tests proved negative. Hydroxychloroquine and colchicine were added to an intensive

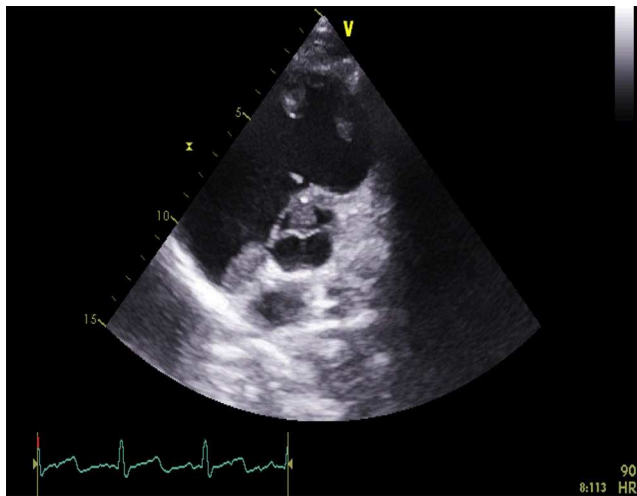


**Image 1.** Apical 5-chamber echocardiogram view showing a thrombus in the right atrium.



**Image 2.** Subcostal echocardiogram view showing a thrombus in the inferior vena cava.

\* Corresponding author.  
E-mail address: [andreviveirosmonteiro@gmail.com](mailto:andreviveirosmonteiro@gmail.com) (A.V. Monteiro).



**Image 3.** Apical 5-chamber echocardiogram view showing thrombi in the right ventricle.

antithrombotic regimen of acenocumarol, enoxaparin and acetylsalicylic acid with a significant reduction of the right atrium and inferior vena cava thrombi and a complete disappearance of the right ventricular masses. The patient improved clinically and no further relapses were observed during follow-up.

### Ethical responsibilities

**Protection of people and animals.** The authors declare that no experiments were performed on humans or animals for this study.

**Data confidentiality.** The authors declare that no patient data appear in this article.

**Right to privacy and informed consent.** The authors declare that no patient data appear in this article.

### Conflict of interest

The authors declare no conflict of interest.

### References

1. Silbiger JJ. The cardiac manifestations of antiphospholipid syndrome and their echocardiographic recognition. *J Am Echocardiogr.* 2009;22:1100–8.
2. Teunisse CC, Kalsbeek AJ, de Vries ST, Huisman SJ, Boers JE, Breeman A, et al. Reversible cardiac valvular disease in catastrophic antiphospholipid syndrome. *Neth J Med.* 2010;68:215–20.
3. Long BR, Leya F. The role of antiphospholipid syndrome in cardiovascular disease. *Hematol Oncol Clin North Am.* 2008;22:79–94, vi–vii.