



Sociedad Española  
de Reumatología -  
Colegio Mexicano  
de Reumatología



## Letter to the Editor

### Cat Scratch Disease During Adalimumab Therapy: A Case Report



#### Enfermedad por arañazo de gato durante el tratamiento con adalimumab: a propósito de un caso

To the Editor,

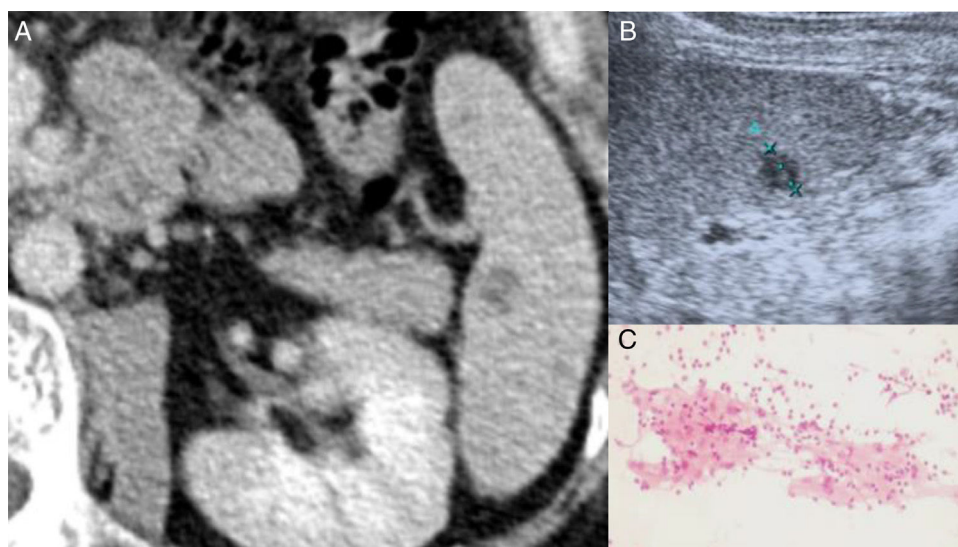
Cat scratch disease (CSD) is an infection caused by *Bartonella henselae* after exposure to infected fleas from cats. Commonly occurs in children and young adults with regional lymphadenopathy and presents a self-limited course.<sup>1</sup> In patients under biological drugs the disease may be severe and disseminated. A differential diagnosis with more common granulomatous infections, like tuberculosis, should be considered in the field of immunosuppression.<sup>2</sup>

The authors report the case of a 38 year-old man diagnosed with Ankylosing Spondylitis (AS) in 2000. He presented inflammatory back pain, anterior uveitis, enthesitis, bilateral sacroiliitis and positive HLA-B27. He was first treated with infliximab (2004–2009) and was after changed to adalimumab because of recurrent uveitis. Before infliximab, he had been treated with isoniazid for latent tuberculosis, following a positive tuberculin skin test.

On December 2013, he referred asthenia and new onset of left axillar nodules lasting for two weeks without fever or other complaints. He had nodules around 30 mm limited to left axillar region, without skin lesions. The cardiopulmonary, abdominal and neurological examinations were unremarkable. He denied known

contacts with tuberculosis patients. He was owner of a cat which frequently scratched him but he did not recall any special lesion. Adalimumab treatment was stopped and diagnostic workup was performed.

Except for Erythrocyte sedimentation rate (38 mm/1st hour) and C Reactive Protein (9.0 mg/L), no others relevant analytical findings were found. Quantiferon–Gold in Tube was negative and thoracic X-ray was normal. Axillar ultrasound examination revealed multiple hypoechoic nodules sized between 20–30 mm. After fine needle aspiration procedure, the cytology revealed granulomatous inflammation (Fig. 1), being Ziehl Neelsen stain, culture for mycobacteria and PCR for: *Mycobacterium (tuberculosis, avium and intracellulare)*, *Borrelia Burgdorferi* and *Nocardia* all negative. The PCR for *Bartonella* spp. was positive as were blood antibodies for *Bartonella henselae* (IgG titer 1:256; IgM <1:32). Due to CSD diagnosis, azithromycin was prescribed for 5 days. After one month, he presented complete regression of lymphadenopathies. Abdominal CT revealed splenic hypodense millimetric nodules and abdominal ultrasound showed two splenic nodules (11 and 8 mm); there was no previous exam to compare (Fig. 1). Regarding procedure risks, it was decided by a multidisciplinary team to avoid splenic biopsy and ciprofloxacin during 3 weeks was prescribed. Regular ultrasound examinations revealed stability of the splenic lesions. Adalimumab was re-started on September 2014 because of exacerbation of AS activity. After more than three years, he remains asymptomatic and abdominal ultrasound revealed slight reduction of splenic nodules (8 and 5 mm).



**Fig. 1.** (A) Contrast-enhanced CT scan of the abdomen reveals a hypodense splenic nodule near the splenic hilum. (B) Abdominal ultrasound of the spleen depicts the same lesion as a hypoechoic nodule without posterior acoustic enhancement. (C) Cytology from lymphadenopathy's fine needle aspiration suggestive of granuloma inflammation.

We herein report, to our knowledge, the second case of CSD on adalimumab treatment. Splenic nodules raised the concern of splenic dissemination of the disease that we cannot certainly attribute to *Bartonella* infection since biopsy was not undertaken. Tuberculosis, being our first concern, was completely excluded. In a retrospective study of adverse event reports on TNF $\alpha$  blockers users, an increased risk of granulomatous infections, particularly tuberculosis, was documented, but only one case was caused by *Bartonella* infection.<sup>2</sup> Later on, 10 CSD reports were described: seven patients were under TNF $\alpha$  blockers (one case on adalimumab), one case on abatacept and two on tocilizumab.<sup>3–11</sup> The majority presented regional lymphadenopathy and had good therapeutic response, restarting biologics 2–3 months after. However, in three published cases, visceral infection presenting with mesenteric panniculitis, splenic nodules and, one of those, with liver granulomatosis, were documented.<sup>3,8,11</sup>

It should be stressed that new onset lymphadenopathy and granulomatosis in patients under biological therapies should raise the suspicion of CSD, particularly in the field of epidemiologic risk. The possibility of systemic dissemination should be kept in mind due to underlying immunosuppression.

### Conflict of Interest

The authors declare they have no conflicts of interest.

### References

1. Carithers HA. Cat-scratch disease: an overview based on a study of 1,200 patients. *Am J Dis Child.* 1985;139:1124–33.
2. Wallis RS, Broder MS, Wong JY, Hanson ME, Beenhouwer DO. Granulomatous infectious diseases associated with tumor necrosis factor antagonists. *Clin Infect Dis.* 2004;38:1261–5.
3. Canas-Ventura A, Esteve E, Horcajada JP, Andreu M, Knobel H, Marquez L. Systemic *Bartonella henselae* infection and Crohn's disease treatment with infliximab. *Inflamm Bowel Dis.* 2012;18:E197–8.
4. Mathieu S, Vellin JF, Poujol D, Ristori JM, Soubrier M. Cat scratch disease during etanercept therapy. *Joint Bone Spine.* 2007;74:184–6.
5. Milin M, Acquitter M, Le Berre R, Sassolas B, Devauchelle-Pensec V, Cornec D. *Bartonella henselae* infection during tocilizumab therapy. *Joint Bone Spine.* 2013;80:221.
6. Orden AO, Nardi NN, Vilaseca AB, Colombini AC, Barrios NG, Vijnovich Baron A. Cat scratch disease during etanercept therapy in a rheumatoid arthritis patient. *Reumatol Clin.* 2017.
7. Osorio F, Pedrosa A, Azevedo F, Figueiredo P, Magina S. Cat-scratch disease during anti-tumor necrosis factor-alpha therapy: case report and review of the literature. *Int J Dermatol.* 2014;53:e182–3.
8. Rossi C, Nasreddine R, Laurent F, Demeulenaere N, Leon M. Beware the cat: *Bartonella henselae* infections and biologic therapies. *Joint Bone Spine.* 2017.
9. Singh N, Sinclair LL, Ijdo J. Cat-scratch fever and lymphadenopathy in a rheumatoid arthritis patient on tocilizumab. *J Clin Rheumatol.* 2015;21:40.
10. Zhou Y, Yin G, Tan C, Liu Y. Cat scratch disease during infliximab therapy: a case report and literature review. *Rheumatol Int.* 2015;35:911–3.
11. Schiffmann A, Pers YM, Lukas C, Combe B, Morel J. Mesenteric and splenic cat-scratch disease during etanercept therapy. *Rheumatology (Oxford).* 2009;48:1461–2.

Teresa Martins-Rocha<sup>a,\*</sup>, Cândida Abreu<sup>b</sup>,  
Alexandra Bernardo<sup>a</sup>, Miguel Bernardes<sup>a,c</sup>, Joanne Lopes<sup>d</sup>

<sup>a</sup> *Rheumatology Department, Centro Hospitalar de São João, Porto, Portugal*

<sup>b</sup> *Infectious Diseases Department, Centro Hospitalar de São João, Porto, Portugal*

<sup>c</sup> *Rheumatology Department, Faculty of Medicine of the University of Porto, Portugal*

<sup>d</sup> *Department of Anatomic Pathology, Centro Hospitalar de São João, Porto, Portugal*

\* Corresponding author.

E-mail address: [teresa.asmr@gmail.com](mailto:teresa.asmr@gmail.com) (T. Martins-Rocha).