



Sociedad Española
de Reumatología -
Colegio Mexicano
de Reumatología

Reumatología Clínica

www.reumatologiaclinica.org



Images in Clinical Rheumatology

The Macaroni sign: The pathognomonic ultrasonography sign of Takayasu arteritis

El signo de Macaroni: el signo de ultrasonido patognomónico de la arteritis de Takayasu

Arghya Chattopadhyay, Sanjay Jain*

Clinical Immunology and Rheumatology Services, Department of Internal Medicine, Postgraduate Institute of Medical Education and Research, Chandigarh, India

ARTICLE INFO

Article history:

Received 18 July 2018

Accepted 4 October 2018

Available online 24 November 2018

An 18-year-old female presented with complaints of low-grade fever, easy fatigability, claudication pain in all four limbs and transient loss of vision in both eyes for last 6 months. On evaluation, she was found to have absent all peripheral pulses along with bruit over the bilateral carotid artery, bilateral sub-clavian artery, over back in the mid-scapular region and left renal artery. On ultrasound B mode scanning of the right carotid artery on longitudinal [Fig. 1a] and transverse [Fig. 1b] cuts, showed homogenous, mid-echoic, circumferential wall thickening, a rare but pathognomonic sign of Takayasu arteritis known as 'Macaroni sign'. Similar findings were present on the left side also. This

uncommon ultrasonography finding was first described by Maeda et al.¹

Takayasu arteritis is a granulomatous vasculitis affecting aorta and its branches, and onset usually before 50 years of age.² The chronic vascular inflammation leads to adventitial thickening, and intima-medial hyperplasia due to cellular infiltrates. Chronic and persistent inflammation leads to fibrosis of the media and intima may resulting into arterial narrowing and, occasionally thrombosis or aneurysm formation.³ Angiography can show the luminal narrowing and extent of involvement but ultrasonography is a better modality of vessel wall assessment.

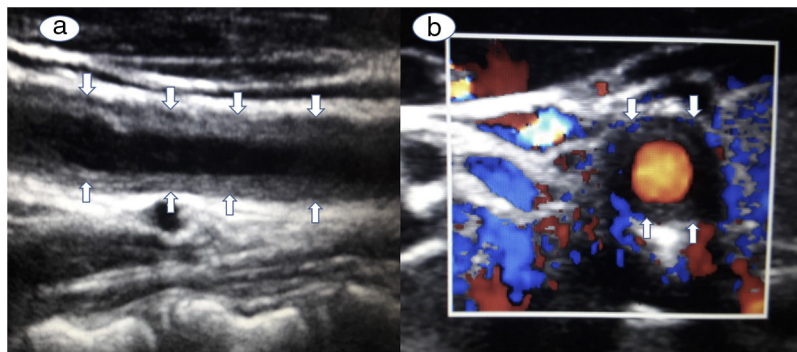


Fig. 1. Ultrasound B mode scanning of the right carotid artery on longitudinal [a] and transverse [b] cuts, showed homogenous, mid-echoic, circumferential wall thickening.

* Corresponding author.

E-mail address: sanjayvanita@yahoo.com (S. Jain).

Consent

Written consent from the patient has been obtained.

Conflict of Interest

None of the authors have any conflict of interest.

References

1. Maeda H, Handa N, Matsumoto M, Hougaku H, Ogawa S, Oku N, et al. Carotid lesions detected by B-mode ultrasonography in Takayasu's arteritis: "macaroni sign" as an indicator of the disease. *Ultrasound Med Biol.* 1991;17:695–701.
2. Jennette JC, Falk RJ, Bacon PA, Basu N, Cid MC, Ferrario F, et al. 2012 Revised International Chapel Hill Consensus Conference nomenclature of vasculitides. *Arthritis Rheum.* 2013;65:1-11.
3. Kerr GS, Hallahan CW, Giordano J, Leavitt RY, Fauci AS, Rottem M, et al. Takayasu arteritis. *Ann Intern Med.* 1994;120:919–29.