




Sociedad Española  
de Reumatología -  
Colegio Mexicano  
de Reumatología

# Reumatología Clínica

www.reumatologiaclinica.org



Images in Clinical Rheumatology

## Neutrophilic Dermatitis of the Hands (Localized Sweet's Syndrome)<sup>☆</sup>



### Dermatitis neutrofilica de las manos (Sweet de las manos)

Belén Lozano-Masdemont,<sup>a,\*</sup> Irene Molina-López,<sup>a</sup> Verónica Parra-Blanco,<sup>b</sup> Ricardo Suárez-Fernández<sup>a</sup>

<sup>a</sup> Servicio de Dermatología, Hospital General Universitario Gregorio Marañón, Madrid, Spain

<sup>b</sup> Anatomía Patológica, Hospital General Universitario Gregorio Marañón, Madrid, Spain

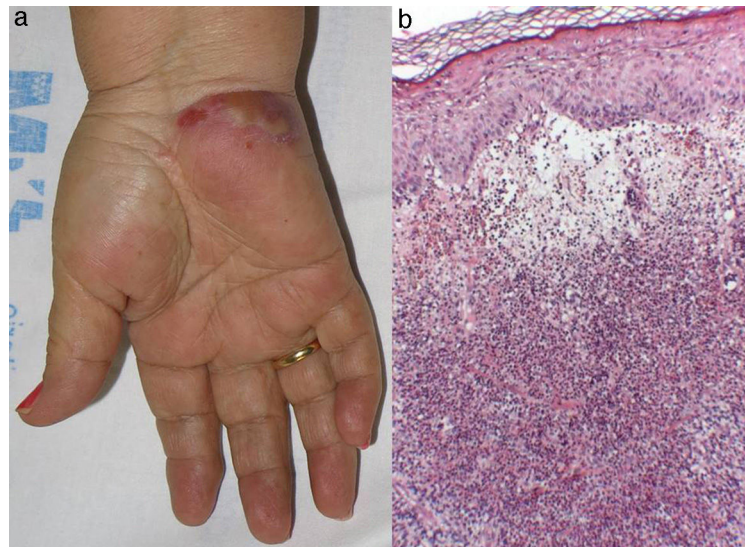
#### ARTICLE INFO

##### Article history:

Available online 31 October 2016

We present the case of a 67-year-old Caucasian woman, who had been diagnosed 9 months before with primary immune thrombocytopenia. She had developed painful palmar lesions 1 week earlier, but had no fever or other accompanying symptoms. We observed erythematous violaceous plaques on the ulnar border of both hands, with a pustule of about 4 cm on the right (Fig. 1a). A

biopsy showed a dense dermic neutrophilic infiltrate, with marked edema, and no vasculitis (Fig. 1b). Cultures to detect bacteria, virus and fungi produced no evidence. Except for the patient's thrombocytopenia, her complete blood count was normal, and laboratory testing found a C-reactive protein of 1 mg/L. A study of the extension ruled out an underlying neoplastic disease. She responded



**Fig. 1.** (a) A large pustule in an erythematous violaceous plaque on the palm of the patient's hand. (b) Hematoxylin and eosin (10×). Dense dermic neutrophilic infiltrate with marked edema, without leukocytoclastic vasculitis.

<sup>☆</sup> Please cite this article as: Lozano-Masdemont B, Molina-López I, Parra-Blanco V, Suárez-Fernández R. Dermatitis neutrofilica de las manos (Sweet de las manos). Reumatol Clin. 2017;13:53–54.

\* Corresponding author.

E-mail address: [belenmasdemont@gmail.com](mailto:belenmasdemont@gmail.com) (B. Lozano-Masdemont).

completely to oral prednisone at 0.5 mg/kg/day for 2 weeks, with no recurrence after 1 year of follow-up. The neutrophilic dermatosis of dorsal hands, recently described,<sup>1</sup> consists of the presence of erythematous violaceous plaques on acral sites, with blisters or pustules, histologically constituted by a dermic neutrophilic infiltrate, with or without association of leukocytoclastic vasculitis.<sup>1–8</sup> Generally, there is no respiratory involvement, fever or laboratory abnormalities, which differentiates it from conventional Sweet's syndrome.<sup>1–5,9</sup> It has been associated with hematologic neoplasms (frequently, myelodysplasia and leukemias), carcinomas, inflammatory bowel disease and arthritis, among other conditions.<sup>1–5</sup> Available data show a rate of association with hematological diseases similar to that of classical Sweet's syndrome.<sup>4,9,10</sup> The case we report is the first that associates it with primary immune thrombocytopenia, a disease that has been found exceptionally in conventional Sweet's syndrome.<sup>10</sup> Our case, although the involvement is palmar, has a characteristic pustular morphology. Thus, we consider the term acral or hand neutrophilic dermatosis to be more correct.<sup>9</sup> The differential diagnosis should include skin infections, arthritis, vasculitis and cutaneous lymphomas. It responds well to oral corticosteroids or dapsone, and its recurrence is occasional.<sup>1–5</sup>

### Ethical Disclosures

**Protection of human and animal subjects.** The authors declare that no experiments were performed on humans or animals for this study.

**Confidentiality of data.** The authors declare that they have followed the protocols of their work center on the publication of patient data.

**Right to privacy and informed consent.** The authors declare that no patient data appear in this article.

### Conflict of Interest

The authors declare they have no conflict of interest.

### References

1. Strutton G, Weedon D, Robertson I. Pustular vasculitis of the hands. *J Am Acad Dermatol.* 1995;32:192–8.
2. Galaria NA, Junkins-Hopkins JM, Kligman D, James WD. Neutrophilic dermatosis of the dorsal hands: pustular vasculitis revisited. *J Am Acad Dermatol.* 2000;43:870–4.
3. DiCaudo DJ, Connolly SM. Neutrophilic dermatosis (pustular vasculitis) of the dorsal hands: a report of 7 cases and review of the literature. *Arch Dermatol.* 2002;138:361–5.
4. Walling HW, Snipes CJ, Gerami P, Piette WW. The relationship between neutrophilic dermatosis of the dorsal hands and Sweet syndrome: report of 9 cases and comparison to atypical pyoderma gangrenosum. *Arch Dermatol.* 2006;142:57–63.
5. Del Pozo J, Sacristán F, Martínez W, Paradelo S, Fernández-Jorge B, Fonseca E. Neutrophilic dermatosis of the hands: presentation of eight cases and review of the literature. *J Dermatol.* 2007;34:243–7.
6. Cook-Norris RH, Youse JS, Gibson LE. Neutrophilic dermatosis of the hands: an underrecognized hematological condition that may result in unnecessary surgery. *Am J Hematol.* 2009;84:60–1.
7. Leecy T, Anderson A, von Nida J, Harvey N, Wood B. Neutrophilic dermatosis of the dorsal hands: an often under recognised and mistreated entity. *Pathology.* 2013;45:198–200.
8. Wang YS, Tan A. Neutrophilic dermatosis of the dorsal hands: an emerging entity. *J Eur Acad Dermatol Venereol.* 2009;23:451–2.
9. Nofal A, Assaf M, Elakad R, Fawzy M, Nofal E. Neutrophilic dermatosis of the dorsal hands: a localized variant of Sweet's syndrome or a distinct entity? *Int J Dermatol.* 2015;54:e66–7.
10. Hensley CD, Caughman SW. Neutrophilic dermatoses associated with hematologic disorders. *Clin Dermatol.* 2000;18:355–67.