




Sociedad Española
de Reumatología -
Colegio Mexicano
de Reumatología

Reumatología Clínica

www.reumatologiaclinica.org



Images in Clinical Rheumatology

Recurrent Stress Fractures in the Feet of a Patient Treated With Antiretrovirals[☆]



Fracturas de fatiga de repetición en pies en un paciente tratado con antirretrovirales

Miguel Ángel Campillo,^a Tarek Carlos Salman Monte,^{a,*} Manel Ciria,^a Jesus Ares^b

^a Servicio de Reumatología, Hospital del Mar, Institut Hospital del Mar d'Investigacions Mèdiques (IMIM), Barcelona, Spain

^b Departamento de Radiología, Hospital del Mar, Barcelona, Spain

ARTICLE INFO

Article history:

Received 5 August 2015

Accepted 25 November 2015

Available online 4 December 2016

Patients with human immunodeficiency virus (HIV) develop bone complications attributable to both the presence of the virus and to the secondary effects of certain antiretroviral drugs. The clinical forms of bone involvement are osteonecrosis, even polyarticular,¹ osteoporosis and osteomalacia.² These last 2 entities are associated with a high risk of fracture.³ Stress fractures have been reported in HIV patients⁴ and, to a greater extent, in HIV patients treated with tenofovir.

We present the case of a male HIV-positive patient (diagnosed in 1999), who began antiretroviral therapy with the following regimen. From September 1999 to November of the same year, he took stavudine (d4T) plus didanosine (ddi) and nelfinavir. In November, he changed to zidovudine (AZT) plus lamivudine (3TC) and nevirapine, which he maintains until July 2008, when he began with emtricitabine, plus tenofovir, as well as nevirapine, until the present time. In 2011, he came to the rheumatology clinic with a 2-month history of pain in the dorsum of his right foot, with no previous injury. He underwent bone scintigraphy using Tc-99m, which revealed a severe trauma in the naviculocuneiform region of the right tarsus and a focal lesion of the third metatarsal bone of the right foot, suggestive of a stress fracture (last densitometry, *T*-score in femur: -2.3 standard deviations [SD]; *T*-score in spine: -2.4 SD) (Fig. 1A). Magnetic resonance imaging (MRI) showed

[☆] Please cite this article as: Campillo MÁ, Salman Monte TC, Ciria M, Ares J. Fracturas de fatiga de repetición en pies en un paciente tratado con antirretrovirales. *Reumatol Clin.* 2017;13:50–52.

* Corresponding author.

E-mail addresses: tareto4@gmail.com, 98383@parcdesalutmar.cat (T.C. Salman Monte).

a clear signal alteration in midfoot, which was manifested as a somewhat lower signal intensity in T1 and an increase in short tau inversion recovery (STIR) sequences, with a discreetly higher signal intensity at the base of the third metatarsal bone. The suggested diagnosis was a stress fracture of right midfoot affecting the naviculocuneiform joint, at the cuboid and third metatarsal bone of the right foot (Fig. 1B). He was treated with nonsteroidal anti-inflammatory drugs (NSAID) and rest. Three months later, the fracture had healed without side effects. In 2012, after an overexertion, the patient presented with mechanical pain in the region of the metatarsus of the left foot. As another stress fracture was suspected, he underwent MRI, which revealed bone edema in the diaphysis of the second metatarsal bone, and in the neighboring soft tissue, consistent with a stress fracture of the second metatarsal bone of the left foot (Fig. 2A and B). He was treated with rest and conservative measures and, the symptoms disappeared in 2 months (plain radiography showed an image of a fracture callus in the diaphysis of the second metatarsal of the left foot (Fig. 2C). On the 30th of January of 2014, the patient returned to the rheumatology clinic, with an increase in the volume of right ankle after another overexertion (a simple walk). Given the possibility of another fracture, he was studied by MRI, which showed a linear image at the level of the talar head, adjacent to the talonavicular joint. He also had a subchondral lesion at the level of the talus (talonavicular joint) with an irregular increase in the talus (Fig. 3A and B).

With a diagnosis that suggested stress fracture of the right talus, the patient was treated with complete rest, the use of 2 crutches, and painkillers. After 3 months, his clinical improvement was complete. The improvement was observed in a new MRI.

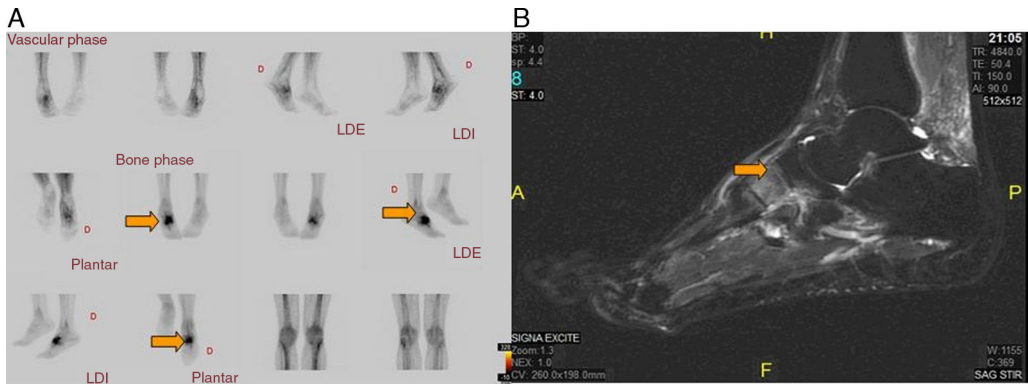


Fig. 1. (A) Bone scintigraphy using ^{99m}Tc , which reveals a severe lesion in the naviculocuneiform region of right tarsus. (B) Sagittal magnetic resonance imaging in short tau inversion recovery (STIR) sequences with an increased signal intensity. More evident at the intermediate cuneiform level and right lateral region.

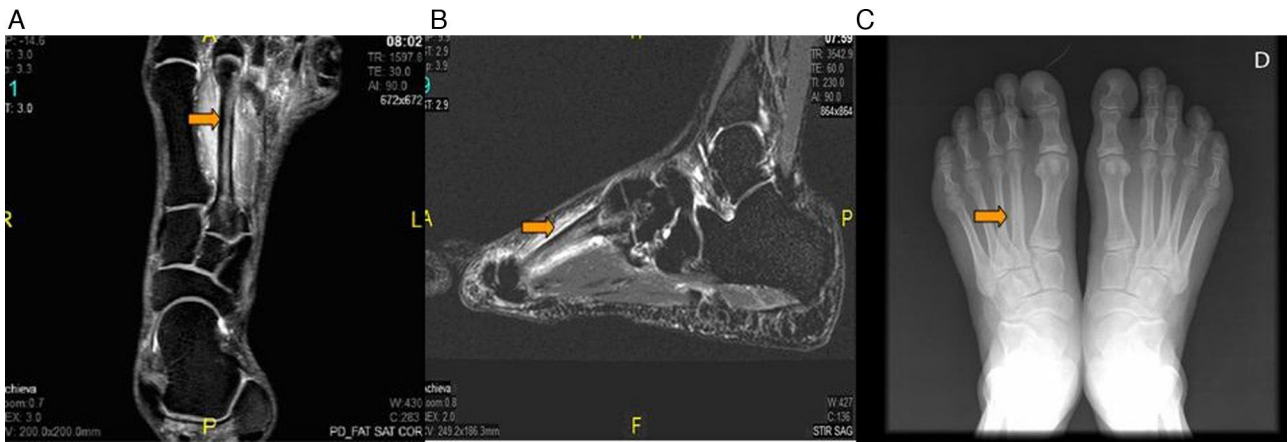


Fig. 2. (A) Coronal magnetic resonance imaging (MRI), with fat saturation, showing bone edema in diaphysis of the second metatarsal of left foot, and in neighboring soft tissue. (B) Sagittal MRI of left foot in short tau inversion recovery (STIR) sequence showing bone edema in diaphysis of the second metatarsal, and in neighboring soft tissue. (C) Plain radiography showing the image of the fracture callus in the diaphysis of the second metatarsal of left foot.

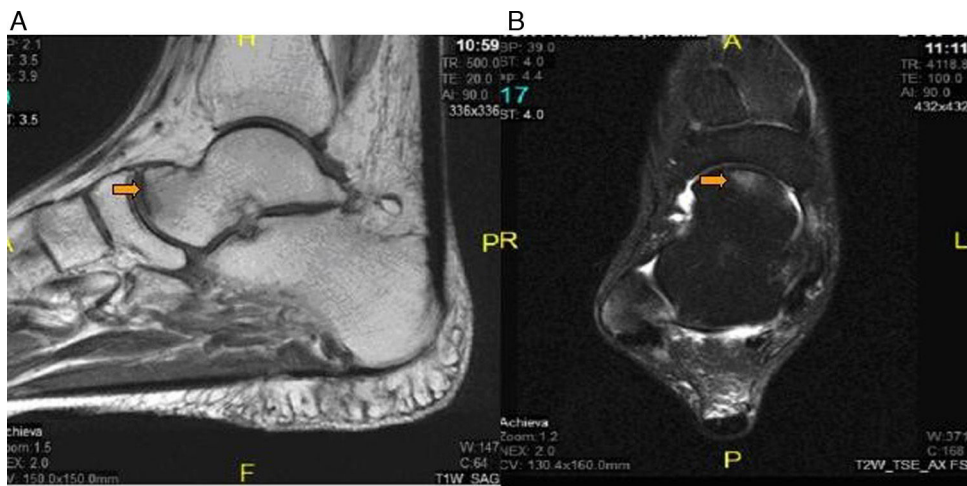


Fig. 3. (A) Sagittal magnetic resonance imaging (MRI) in T1-weighted sequence, showing the focal lesion at the level of the talar head with diffuse edema in other bones of right foot. (B) Axial MRI of the foot in T2-weighted sequence, with fat saturation, showing focal lesion at level of the talar head and joint effusion at the level of anterior and posterior tibiotalar joint of right foot.

Ethical Disclosures

Protection of human and animal subjects. The authors declare that no experiments were performed on humans or animals for this study.

Confidentiality of data. The authors declare that they have followed the protocols of their work center on the publication of patient data.

Right to privacy and informed consent. The authors have obtained the written informed consent of the patients or subjects mentioned in the article. The corresponding author is in possession of this document.

Conflicts of Interest

The authors declare they have no conflicts of interest.

References

1. Mateo L, Holgado S, Mariñoso ML, Pérez-Andrés R, Bonjoch A, Romeu J, et al. Hypophosphatemic osteomalacia induced by tenofovir in HIV-infected patients. *Clin Rheumatol.* 2014 [Epub ahead of print].
2. Cotter AG, Powderly WG. Endocrine complications of human immunodeficiency virus infection: hypogonadism, bone disease and tenofovir-related toxicity. *Best Pract Res Clin Endocrinol Metab.* 2011;25:501–15.
3. Prieto-Alhambra D, Güerri-Fernández R, de Vries F, Lalmohamed A, Bazelier M, Starup-Linde J, et al. HIV infection and its association with an excess risk of clinical fractures: a nationwide case-control study. *J Acquir Immune Defic Syndr.* 2014;66:90–5.
4. Paccou J, Viget N, Legrouit-Gérot I, Yazdanpanah Y, Cortet B. Bone loss in patients with HIV infection. *Joint Bone Spine.* 2009;76:637–41.