

In the case of this patient we found no other condition to explain the dysphonia.

In conclusion, BD should be taken into account in the differential diagnosis of sudden dysphonia in the absence of other more common findings, especially in regions in which the disease is frequent.

## References

1. Singer O. Cogan and Behcet syndromes. *Rheum Dis Clin N Am.* 2015;41:75–91.
2. Morales-Angulo P, Vergara P, Obeso-Agüero S, Acle L, Gonzalez-Gay MA. Manifestaciones otorrinolaringológicas en pacientes con enfermedad de Behcet. *Acta Otorrinolaringol Esp.* 2014;65:15–21.
3. Al-Araji A, Kidd D. Neuro-Behçet's disease: epidemiology, clinical characteristics, and management. *Lancet Neurol.* 2009;8:192–204.
4. Pirildar T, Celik O. Sudden Hoarseness due to unilateral cord vocal paralysis in a patient with Behcet's disease. *Clin Rheumatol.* 2003;22:254–5.
5. Karabudak O, Dogru S, Dogan B, Harmayeri Y. Unilateral vocal cord paralysis in a patient with Behcet's disease. *J EADV.* 2007;21:1413–50.

Elvis Amao-Ruiz,<sup>a,\*</sup> Ana María Correa-Fernández,<sup>b</sup> Jesús Gallego-Gil<sup>c</sup>

<sup>a</sup> Servicio de Cardiología, Hospital Clínico de Valladolid, Valladolid, Spain

<sup>b</sup> Unidad de Insuficiencia Cardíaca y Trasplante, Servicio de Cardiología, Hospital Clínico de Valladolid, Valladolid, Spain

<sup>c</sup> Servicio de Medicina Interna, Hospital Clínico de Valladolid, Valladolid, Spain

\* Corresponding author.

E-mail address: [tatojar@outlook.com](mailto:tatojar@outlook.com) (E. Amao-Ruiz).

2173-5743/

© 2016 Elsevier España, S.L.U. and Sociedad Española de Reumatología y Colegio Mexicano de Reumatología. All rights reserved.

## Osteosarcoma in Tophaceous Gout: A Case Report and Literature Review<sup>☆</sup>



### *Osteosarcoma en gota tofácea: descripción de un caso clínico y revisión de la literatura*

To the Editor,

Gout is a disease that involves the deposit of monosodium urate (MSU) crystals, which mostly affects men, and constitutes the most common cause of arthritis in that gender. On occasion, it can lead to accumulations of crystals of variable size and location referred to as tophi. Considered to be a “mimicking” disease, gout can simulate, among others, infectious or neoplastic processes. We report the case of a patient with gout who developed an osteosarcoma arising at the site of a preexisting tophus.

The patient was a 65-year-old man with tophaceous gout who had been followed at another center and was referred to us by way of the medical oncology department for the management an acute attack of polyarthralgia and olecranon bursitis after a transfusion while undergoing chemotherapy. He had been diagnosed a year earlier with osteosarcoma on the dorsum of his foot arising at the location of a tophus that had been removed 7 months before, after pathological confirmation (Fig. 1) and negative findings in the study of the extension. It required infracondylar amputation and preoperative and postoperative chemotherapy with cisplatin and adriamycin. He had been taking allopurinol for 3 years (up to 300 mg/day), and employed colchicine and/or nonsteroidal anti-inflammatory drugs during attacks. He had levels of uric acid in blood of up to 8 mg/dL, and began to have symptoms at the age of 40 years with podagra, and later developed tophi in the olecranon bursa and the dorsum of his foot. The inflammatory attack was resolved with low-dose prednisone and aspiration of the olecranon bursa. Gram staining and culture of the fluid obtained were negative, and a study with polarized light microscopy revealed the presence of MSU crystals. He was discharged and began colchicine at 1 mg/day after gradual interruption of prednisone therapy. During follow-up, he changed from allopurinol to febuxostat (at a dose

of 80 mg/day), which achieved optimization of his uric acid level in blood and progressive dissolution of the olecranon tophi. Several months later, colchicine was discontinued and he continued to take febuxostat at the same dose. He has not had any further attacks and maintains his level of uric acid at 5 mg/dL. In May of 2016, he developed an “in-transit” recurrence of the neoplastic disease, with a superficial mass in ipsilateral thigh that required local resection and chemotherapy (ifosfamide).

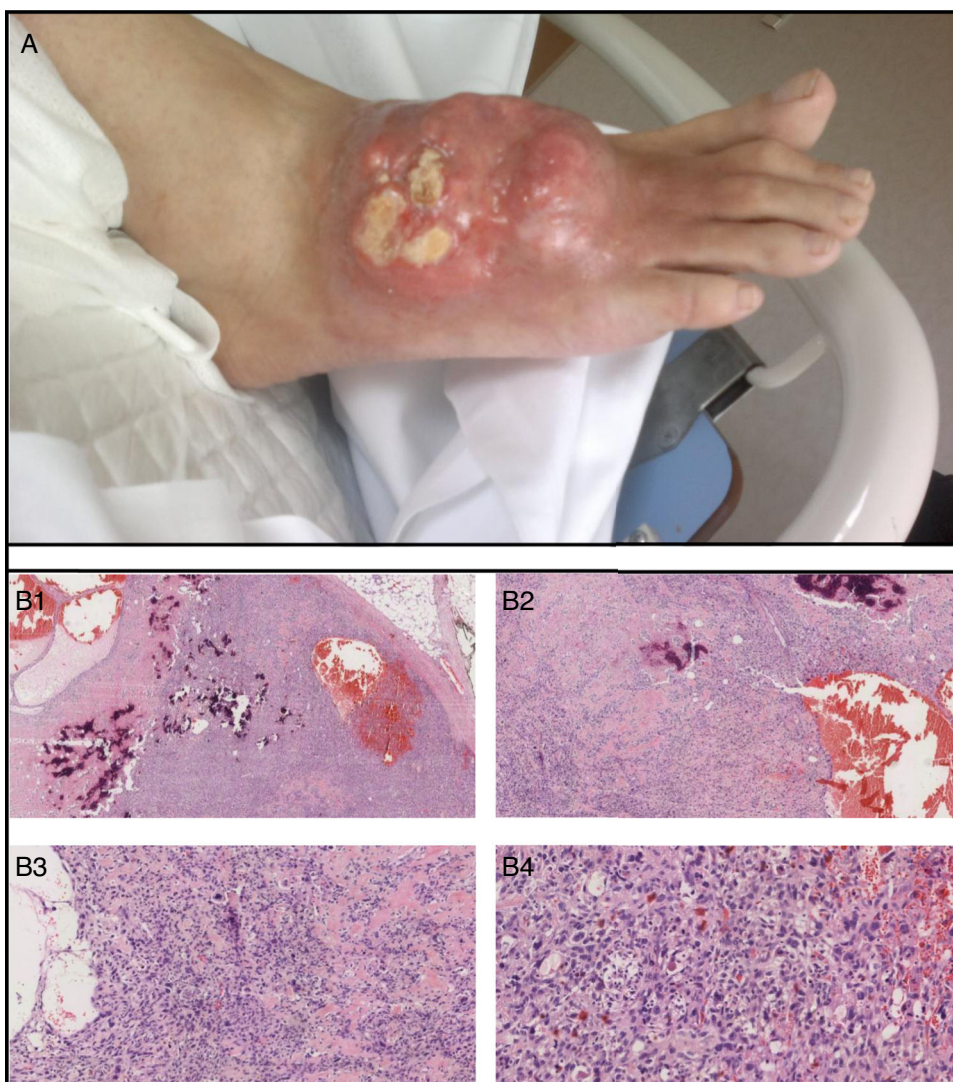
Gout is the most common cause of arthritis in men, and is originated by deposits of MSU crystals in tissues. Some patients develop tophi (subcutaneous, periarticular or intraarticular crystal accumulations) which can have a marked inflammatory activity and present calcifications or ossifications as they increase in size.<sup>1–3</sup> Moreover, tophi can mimic infectious or neoplastic processes and become superinfected or undergo malignant transformation, having an adverse effect on the prognosis of the patient.

A number of publications have reported tumors that arise at the sites of tophi.<sup>4–9</sup> All occurred in extremities of middle-aged or elderly men and involved recurrences or metastasis. There are descriptions of benign neoplasms such as giant cell tumors or malignant diseases such as different sarcomas (undifferentiated pleomorphic sarcoma, cutaneous angiosarcoma or fibrosarcoma).

The authors of these articles provide interesting hypotheses such as the role of prolonged hyperuricemia and the severity of the MSU deposit as factors leading to secondary cell transformation toward inflammation,<sup>8</sup> or the theory of sarcoma associated with a foreign body, similar to those originated by other materials.<sup>7,10</sup>

Sarcomas are mesenchymal tumors originating from connective tissue (fibrosarcoma), cartilage (chondrosarcoma), bone (osteosarcoma), endothelium (angiosarcoma), etc. Although there may be a certain underestimation of the incidence of these neoplasms in gout, sarcomas seem to be uncommon, but occasionally are aggressive. Thus, they should be included in the differential diagnosis in the case of a subcutaneous or periarticular mass in a patient with gout or with the atypical complication of a preexisting tophus.

<sup>☆</sup> Please cite this article as: Calvo Aranda E, Rodríguez Pérez I, Rodríguez-Pascual J, García de la Peña Lefebvre P. Osteosarcoma en gota tofácea: descripción de un caso clínico y revisión de la literatura. *Reumatol Clin.* 2017;13:307–309.



**Fig. 1.** High-grade osteosarcoma on the dorsum of right foot in a patient with tophaceous gout. (A) Macroscopic description: tumor-like infiltrated erythematous violaceous plaque measuring 6 cm in maximum diameter, composed of hard tumor nodules, with the consistency of bone and petrified. The surface consisted of excrement tumor lesions that were slightly pedicled measuring about 3 cm in diameter. (B) Microscopic description (hematoxylin and eosin [H&E]; from upper left to right and lower left to right: B1: H&E 2 $\times$ ; B2: H&E 4 $\times$ ; B3: H&E 10 $\times$ ; B4: H&E 20 $\times$ ). Telangiectatic osteosarcoma, with abundant osteoid formation and blood-filled spaces and no epithelial lining. At high magnification, it is possible to observe large cells with irregular and pleomorphic nuclei, and numerous mitoses, many atypical.

## Acknowledgments

To the Pathology and Medical Oncology Departments of Grupo HM Hospitales, Madrid, Spain.

## References

- Pérez-Ruiz F, Urresola A, Gorostiza D, Canteli B. Validation of the measurement of tophi with magnetic resonance imaging as an outcome measure for chronic gout. *Arthritis Rheum.* 2011;63 Suppl. 10:S208.
- Yu JS, Chung C, Recht M, Dailiana T, Jurdi R. MR imaging of tophaceous gout. *AJR Am J Roentgenol.* 1997;168:523–7.
- Popp JD, Bidgood WD Jr, Edwards NL. Magnetic resonance imaging of tophaceous gout in the hands and wrists. *Semin Arthritis Rheum.* 1996;25:282–9.
- Pérez-Mies B, Ruiz de la Parte A, Echevarría Iturbe C, García Higuera I, Velasco Osés A, Terán Saavedra P. Fibrohistiocitoma maligno (sarcoma pleomórfico indiferenciado de alto grado) sobre tofo gotoso. *Rev Esp Patol.* 2006;39:113–6.
- Carnero S, Terán P, Trillo E. Malignant fibrous histiocytoma arising in a gouty tophus at the second metacarpophalangeal joint. *J Plast Reconstr Aesthet Surg.* 2006;59:775–8.
- Szlabi S, Flores JO, Diller AL, Cabrera M. Undifferentiated high grade pleomorphic sarcoma/malignant fibrous histiocytoma associated a gouty tophus. A case report. *Rev Fac Cien Med Univ Nac Cordoba.* 2012;69:224–7.
- Folpe AL, Johnston CA, Weiss SW. Cutaneous angiosarcoma arising in a gouty tophus: report of a unique case and a review of foreign material-associated angiosarcomas. *Am J Dermatopathol.* 2000;22:418–21.
- Schuind FA, Stallenberg B, Rimmelink M, Pasteels JL. Associated giant cell tumor and tophaceous deposits in a finger pulp: a case report. *J Hand Surg Am.* 2003;28:871–4.
- Wang JJ, Wang HY, Cheng K, Wang X, Yu B, Shi SS, et al. Fibrosarcoma arising from gouty tophi: report of a unique case and review of literature. *Int J Clin Exp Pathol.* 2015;8:4227–32.
- Kaplan M, İyiköşker Hİ. A new complication of retained surgical gauze: development of malignant fibrous histiocytoma—report of a case with a literature review. *World J Surg Oncol.* 2012;10:1–5.

Enrique Calvo Aranda,<sup>a,\*</sup> Irene Rodríguez Pérez,<sup>b</sup>  
Jesús Rodríguez-Pascual,<sup>c</sup> Paloma García de la Peña Lefebvre<sup>a</sup>

\* Corresponding author.

E-mail address: [ecalvoa@hotmail.com](mailto:ecalvoa@hotmail.com) (E. Calvo Aranda).

<sup>a</sup> *Servicio de Reumatología, HM Hospitales, Hospital Universitario HM Sanchinarro, Madrid, Spain*

<sup>b</sup> *Servicio de Anatomía Patológica, HM Hospitales, Hospital Universitario HM Sanchinarro, Madrid, Spain*

<sup>c</sup> *Servicio de Oncología Médica, HM Hospitales, Hospital Universitario HM Sanchinarro, Madrid, Spain*

2173-5743/

© 2016 Elsevier España, S.L.U. and Sociedad Española de Reumatología y Colegio Mexicano de Reumatología. All rights reserved.