



Sociedad Española
de Reumatología -
Colegio Mexicano
de Reumatología

Reumatología Clínica

www.reumatologiaclinica.org



Letters to the Editor

Is gout an easy-to-treat disease? The importance of health determinants



¿Es la gota una enfermedad fácil de tratar? La importancia de los determinantes de salud

Dear Editor,

The patient is a 60-year old man we attended during a rheumatology campaign at his hometown, Etzatlán, Mexico. He has a 30-year history of gout and presented widespread tophus formation with extensive structural damage (Fig. 1). Based on the model of health determinants described by the WHO,¹ we depict the failures that explain why a supposedly easy-to-treat disease² progressed to polyarticular chronic tophaceous gout with multidimensional impact.

Genes predispose to the disease but do not determine outcomes. Regarding education and individual lifestyle, the patient had 2 years of schooling, frequently drank alcohol, and had a strong internal locus of control. Regarding healthcare services, the patient attended over 25 general practitioners (GPs), receiving different prescriptions and several contradictory indications, mainly on how to take allopurinol which varied from daily suboptimal doses to periodic use as “prophylaxis” when the patient planned to drink alcohol. The patient visited a rheumatologist once, who explained the disease in detail and how to treat it. But the patient did not understand and

the rheumatologist did not make sure he understood. In fact, the patient perceived great disagreement among the visited physicians, so he decided what to do: take bethametasone, limit alcohol intake to weekends, and assigned allopurinol as the cause of worsening because every time he took it had an acute attack. Community and social networks also failed. He always attended medical appointments alone; his wife and children are resentful because he has not worked for the last 15 years and his children had to start working, which prevented them from attending high school. The socioeconomic and cultural conditions, such as myths surrounding the disease, the use of nonconventional therapies, and living in a small town without specialized medical services also had a negative impact.

Unfavorable health determinants may explain the reported increase in severity of gout in several countries^{3–7}; there are several protagonists involved on these. In the sense of shared responsibility, the poor outcome of this patient, and of many others as reported in the literature, can be assigned not only to the patient's behavior, but also to GPs and their misconceptions; the inefficiency of social and community networks; the rheumatologist and his unadjusted communication skills towards his patient's culture; the health-care system and its inability to care for people beyond the activities of diagnosing and prescribing drugs to just the ones that attend to the clinics, etc. Perhaps if only one of the protagonists had done his job well, such multidimensional impact of an “easy-to-treat disease” would not have occurred.

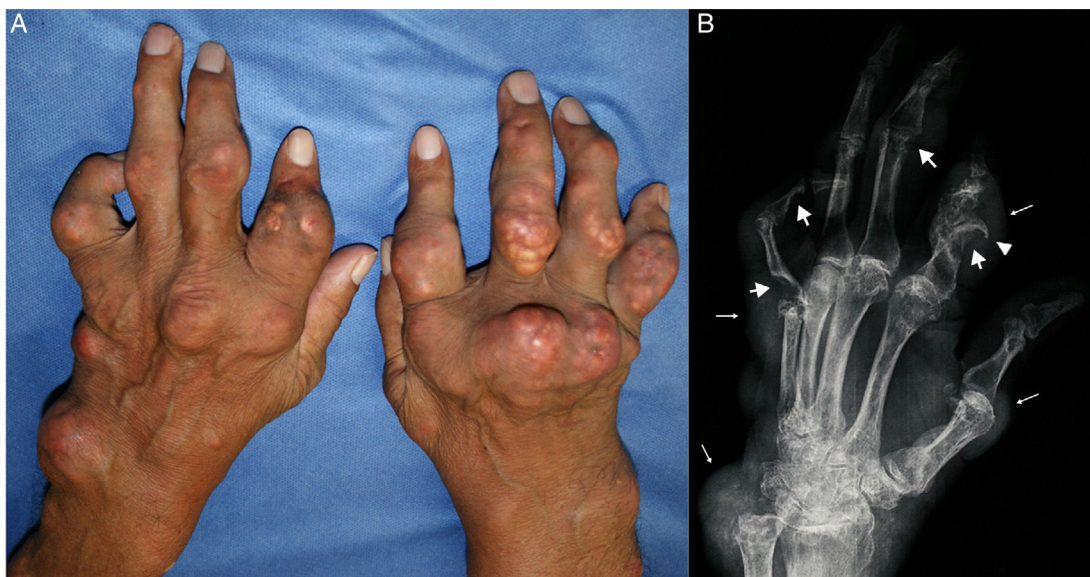


Fig. 1. (A) Tophaceous gout with multiple tophi on both hands. (B) The left hand X-ray shows punched-out erosions (thick arrows) with overhanging edges (arrowhead) and soft tissue nodules (thin arrows), findings suggestive of gout.

Funding

None.

Conflict of interest

The authors declare that they have no conflict of interest.

Acknowledgements

None.

References

1. World Health Organization. Health Impact Assessment (HIA): the determinants of health. [consulted 20 Dec 2016]. Available: <http://www.who.int/hia/evidence/doh/en/>
2. Lindsay K, Gow P, Vanderpyl J, Logo P, Dalbeth N. The experience and impact of living with gout: a study of men with chronic gout using a qualitative grounded theory approach. *J Clin Rheumatol*. 2011;17:1–6. <http://dx.doi.org/10.1097/RHU.0b013e318204a8f9>.
3. López López CO, Lugo EF, Álvarez-Hernández E, Peláez-Ballestas I, Burgos-Vargas R, Vázquez-Mellado J. Severe tophaceous gout and disability: changes in the past 15 years. *Clin Rheumatol*. 2017;36:199–204. <http://dx.doi.org/10.1007/s10067-016-3381-z>.
4. Lim SY, Lu N, Oza A, Fisher M, Rai SK, Menendez ME, Choi HK. Trends in Gout and Rheumatoid Arthritis Hospitalizations in the United States, 1993–2011. *JAMA*. 2016;315:2345–7. <http://dx.doi.org/10.1001/jama.2016.3517>.

5. Kuo CF, Grainge MJ, Mallen C, Zhang W, Doherty M. Eligibility for and prescription of urate-lowering treatment inpatients with incident gout in England. *JAMA*. 2014;312:2684–6. <http://dx.doi.org/10.1001/jama.2014.14484>.
6. Wood R, Fermer S, Ramachandran S, Baumgartner S, Morlock R. Patient with Gout treated with conventional urate-lowering therapy: association with disease control, health-related quality of life, and work productivity. *J Rheumatol*. 2016;43:1897–903. <http://dx.doi.org/10.3899/jrheum.151199>.
7. Nasser-Ghods N, Harrold LR. Overcoming adherence issues and other barriers to optimal care in gout. *Curr Opin Rheumatol*. 2015;27:134–8. <http://dx.doi.org/10.1097/BOR.0000000000000141>.

Aldo Barajas-Ochoa,^{a,*} Jose Juan Castaneda-Sanchez,^b
Cesar Ramos-Remus^c

^a Unidad de Investigación en Enfermedades Crónico-Degenerativas, Providencia, Guadalajara, Mexico

^b Unidad de Investigación en Enfermedades Crónico-Degenerativas, Guadalajara, Mexico

^c Universidad Autónoma de Guadalajara, Guadalajara, Mexico

* Corresponding author.

E-mail address: aldouch5@gmail.com (A. Barajas-Ochoa).

2173-5743/

© 2017 Elsevier España, S.L.U. and Sociedad Española de Reumatología y Colegio Mexicano de Reumatología. All rights reserved.

Response to: Madelung deformity[☆]**En respuesta a: Deformidad de Madelung**

To the Editor,

We read the publication by Ly-Pen and Andreu¹ in REUMATOLOGÍA CLÍNICA with great attention. They reported the case of a 39-year-old woman who had been diagnosed with bilateral carpal tunnel syndrome secondary to Madelung's deformity. She received a local injection of triamcinolone, which improved the symptoms. We would like to express our experience in the pediatric rheumatology unit of our hospital.

Madelung's deformity is a dysplasia of the distal radial physis. Its early closure is accompanied by a progressive deformity with dorsal dislocation of the ulna and palmar carpal displacement and, thus, supination and rotation are limited. It affects girls between the ages of 8 and 12 years, and is generally bilateral. This disorder is associated with a number of syndromes such as Leri-Weill dyschondrosteosis, Hurler syndrome, Turner syndrome, chondrodysplasia and Ollier disease.

We report the case of a 14-year-old girl who in October 2015 had been diagnosed with Leri-Weill syndrome. The disease was detected incidentally in a radiograph carried out due to a traumatic injury. She had mutations in the Short Stature Homeobox-containing (*SHOX*) gene and in pseudoautosomal region 1 (*PAR1*) in 5'. She was referred to pediatric rheumatology by her endocrinologist as she complained of mechanical pain in both carpi that had increased progressively in the preceding months and had a poor response to ibuprofen. The results of physical examination were consistent with bilateral Madelung's deformity, with pain on dorsal flexion of both carpi, with no



Fig. 1.

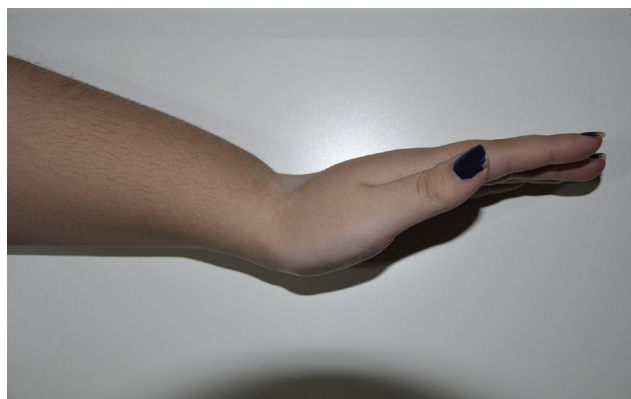


Fig. 2.

[☆] Please cite this article as: Muñoz Calonge MA, Murias Loza SM, Itza N. En respuesta a: Deformidad de Madelung. *Reumatol Clin*. 2018;14:60–61.