



Sociedad Española
de Reumatología -
Colegio Mexicano
de Reumatología



Images in Clinical Rheumatology

Antisynthetase Syndrome and Influenza B, Characteristic Pulmonary Involvement[☆]

Síndrome antisintetasa e influenza B, afectación pulmonar característica

Roberto Hurtado García,* Beatriz Hurtado Oliver, Eric Nortes Cañizares, José Maria Cepeda Rodrigo

Servicio de Medicina Interna, Hospital Vega Baja, Orihuela, Alicante, Spain

ARTICLE INFO

Article history:

Received 28 September 2016

Accepted 24 November 2016

Available online 1 May 2018

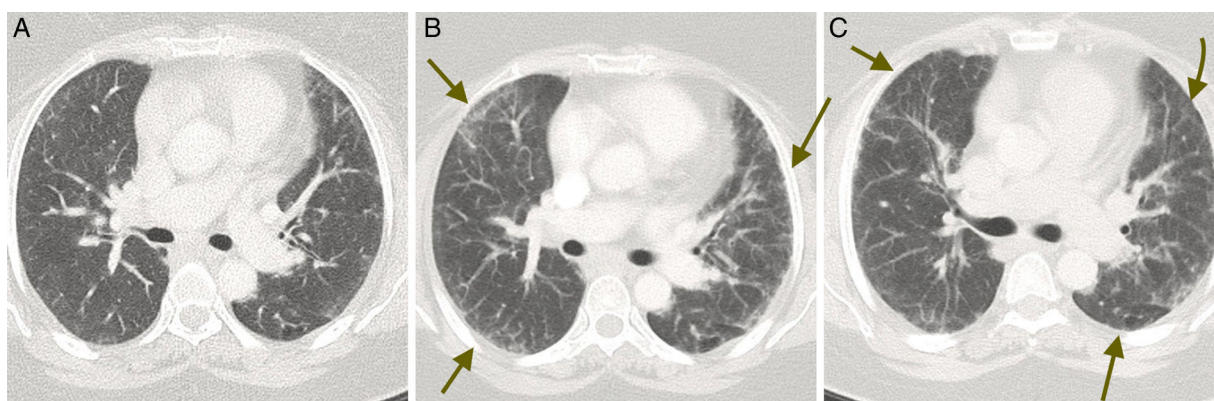


Fig. 1. Serial computed tomography scans taken in the axial plane: (A) initial phase, (B) high point of the process and (C) resolution.

The figure shows small bilateral patchy ground-glass opacities, predominantly in the periphery, as a key finding (arrows), and a slight thickening of the interstitium between lobes.

We present the case of a 54-year-old woman who had been diagnosed with antisynthetase syndrome (positive for anti-Ro 52 antibodies and OC) with interstitial lung involvement and concomitant autoimmune hepatitis. She was being treated with azathioprine, etanercept and prednisone, at a dose of 15 mg/day that was being tapered. She was admitted to the hospital with manifestations of an increase in her usual dyspnea, fever of 38.5 °C and yellowish expectoration. With these findings, we requested that she undergoes lung computed tomography, which revealed

the presence of recently developed patchy ground-glass opacities. Given the clinical context, we were obliged to rule out superinfection; we also observed areas of fibrotic scar in middle and lower fields, in the form of subpleural interstitial thickening, traction bronchiectasis and bronchiolectasis. She underwent serological tests for cytomegalovirus, Epstein–Barr virus and varicella zoster, which were negative. There were no microorganisms in her sputum. However, polymerase chain reaction for influenza B virus was positive. The patient was treated with antibiotic therapy consisting of piperacillin-tazobactam combined with oseltamivir. Her clinical response was good, as is shown by the radiological improvement, illustrated by the serial images (A initial findings, B with patchy infiltrations and C showing resolution) (Fig. 1).

The population of immunocompromised patients has increased in recent years. This has been accompanied by those having

[☆] Please cite this article as: Hurtado García R, Hurtado Oliver B, Nortes Cañizares E, Cepeda Rodrigo JM. Síndrome antisintetasa e influenza B, afectación pulmonar característica. Reumatol Clin. 2018;14:173–174.

* Corresponding author.

E-mail address: robex2@hotmail.com (R. Hurtado García).

the associated infectious complications, especially, pneumonia (approximately 75% of these infections¹). The agents that cause pneumonia in these patients, may be the same as those reported in immunocompetent individuals (although it is associated with higher rates of morbidity and mortality), that is to say, viruses like influenza, cytomegalovirus, herpes simplex and varicella zoster.²

Complications due to influenza virus occur more often in elderly and diabetic patients, as well as in individuals with renal dysfunction or immunosuppressive therapy. Their clinical manifestations are diffuse in the initial phases and become worse as the diseases advance. In radiological terms, they are characterized by diffuse interstitial infiltrates.³ Although this case report corresponds to what we may observe in routine clinical practice, we have found no similar cases described in the literature.

Ethical Disclosures

Protection of human and animal subjects. The authors declare that no experiments were performed on humans or animals for this study.

Confidentiality of data. The authors declare that they have followed the protocols of their work center on the publication of patient data.

Right to privacy and informed consent. The authors declare that no patient data appear in this article.

Conflict of interest

The authors declare they have no conflicts of interest.

References

1. Oh YW, Effmann EL, Godwin JD. Pulmonary infections in immunocompromised hosts: the importance of correlating the conventional radiologic appearance with the clinical setting. *Radiology*. 2000;217:647–56.
2. Ishiquro T, Takayanagi N, Kanauchi T, Uozumi R, Kawate E, Takaku Y, et al. Clinical and radiographic comparison of influenza virus-associated pneumonia among three viral subtypes. *Intern Med*. 2016;55:731–7.
3. Serebioakova OM, Romanova EN, Govorin AV, Filev AP, Shangin AS. Peculiarities of clinical and X-ray picture of pneumonia in patients with influenza A (H1N1). *Klin Med (Mosk)*. 2012;90:70–2.