



Sociedad Española
de Reumatología -
Colegio Mexicano
de Reumatología

Reumatología Clínica

www.reumatologiaclinica.org



Case Report

Neuroimmunological Response in Neuro-Behçet's[☆]

Alexis Alejandro Garcia-Rivero,^a Javier Gonzalez-Argote,^{a,*} José Pedro Martínez Larrarte,^b
Ivonne Margarita Iglesias González,^b Alberto Juan Dorta-Contreras^b

^a Instituto de Ciencias Básicas y Preclínicas Victoria de Girón, Universidad de Ciencias Médicas de La Habana, La Habana, Cuba

^b Laboratorio Central del Líquido Cefalorraquídeo (LABCEL), Facultad de Ciencias Médicas Miguel Enríquez, Universidad de Ciencias Médicas de La Habana, La Habana, Cuba



ARTICLE INFO

Article history:

Received 27 September 2016

Accepted 10 February 2017

Available online 17 August 2018

Keywords:

Blood–cerebrospinal fluid barrier

Behçet's disease

Immunoglobulins

Neuro-Behçet's disease

Reibergram

Intrathecal synthesis

ABSTRACT

Behçet's disease is a chronic, multisystem, autoimmune vasculitis characterised by a triad of key signs. We report the case of a 16-year-old Caucasian girl, who complained of headache, dizziness and paresis of the left side of her body. After physical examination and ancillary tests, she was diagnosed with Behçet's disease with neurological manifestations (neuro-Behçet's disease). She had a good response to treatment. IgG, IgA, IgM and albumin were quantified in serum and cerebrospinal fluid by single radial immunodiffusion. Intrathecal synthesis was found for the three classes of immunoglobulins. This is the first case in which the Reibergram was used to evaluate the neuroimmunological response in a patient with Behçet's disease, suggesting the use of this diagnostic means for the active phase of the disease.

© 2017 Elsevier España, S.L.U. and Sociedad Española de Reumatología y Colegio Mexicano de Reumatología. All rights reserved.

Respuesta neuroinmunológica en neuro-Behçet

RESUMEN

La enfermedad de Behçet es una vasculitis crónica, multisistémica y autoinmune caracterizada por una tríada de signos claves presentes en los pacientes que la padecen. Se presenta una paciente femenina, caucásica, de 16 años, con cefalea, mareos y paresia en hemicuerpo izquierdo que, tras examen físico y métodos complementarios, se diagnosticó como enfermedad de Behçet con manifestaciones neurológicas (neurobehçet), y a la que se impuso tratamiento, con buena respuesta. Se cuantificó IgG, IgA, IgM y albúmina en suero y LCR, por inmunodifusión radial simple, encontrándose síntesis intratecal de las 3 clases de inmunoglobulinas mayores. Los hallazgos en este caso constituyen el primer estudio donde se utiliza el reibergrama para evaluar la respuesta neuroinmunológica en un paciente con enfermedad de Behçet, siendo indicativo este medio diagnóstico de fase activa de la enfermedad.

© 2017 Elsevier España, S.L.U. y Sociedad Española de Reumatología y Colegio Mexicano de Reumatología. Todos los derechos reservados.

Palabras clave:

Barrera sangre-líquido cefalorraquídeo

Enfermedad de Behçet

Inmunoglobulinas

Neurobehçet

Reibergrama

Síntesis intratecal

[☆] Please cite this article as: Garcia-Rivero AA, Gonzalez-Argote J, Martínez Larrarte JP, Iglesias González IM, Dorta-Contreras AJ. Respuesta neuroinmunológica en neurobehçet. Reumatol Clín. 2019;15:117–120.

* Corresponding author.

E-mail address: jargote@infomed.sld.cu (J. Gonzalez-Argote).

Introduction

Neuro-Behçet (NB) is the product of the primary impact of Behçet's disease on the CNS, systemic manifestations of neurological complications or it may be secondary to treatment.¹

Immunological studies of cerebrospinal fluid (CSF) in this entity were confined to the quantifying of some immunoglobulins.^{2,3}

The Reibergram makes an integrated analysis of the functioning of the blood/CSF barrier and the intrathecal synthesis of immunoglobulins from serum and LCF coupling (Fig. 1). This method is a useful tool for diagnosing diseases which involve the CNS.^{4,5}

The aim of this article is to assess the neuroimmunological response through the Reibergram in a patient with NB.

Clinical Case

We report the case of a female, Caucasian patient aged 16 who presented with headaches (occipital) and back pain on the left side of her body, of 15 days onset. Five days later she suffered from dizziness and paresis on the left side of her body which made walking impossible.

Neurological examination highlighted cranial nerve VI paralysis and bilateral papilloedema. Four days after admittance an ulcer appeared in the labia majora region, and the patient was questioned again and stated having a prior history of oral aphthous ulcers on at least 3 occasions in the last year, which were not resolved with standard treatment and which disappeared spontaneously. The pathergy skin test was positive.

Erythrocyte sedimentation rate: 84 mm/h. Blood chemistry, complete haemogram and coagulation profile tested within normal parameters. Computerised tomography informed of diffuse cortical atrophy, and cytochemical, microbiological and cytological analyses of the CSF produced normal results.

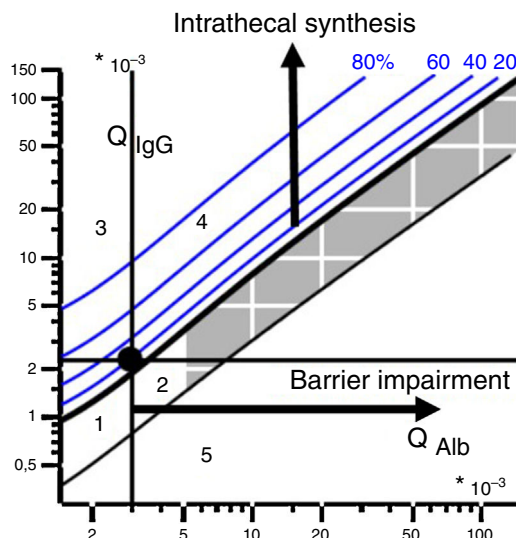
IgG, IgA, IgM and albumin concentration were quantified in serum and CSF by single radial immunodiffusion. The result of this neuroimmunological study revealed intrathecal synthesis for the three classes of the largest immunoglobulins, as a synthesis pattern, without any impairment of the blood/CSF barrier, concluding that this was an inflammatory process of the CNS (Fig. 2, Reibergram 1).

The patient was diagnosed with NB and treatment was administered with methylprednisolone to which she responded favourably.

Four months later the patient had a relapse with neurological symptoms (paralysis of the III, IV, VI and V—ophthalmic branch—cranial nerves) and ophthalmological nerves (anterior uveitis and chronic bilateral papilloedema).

Erythrocyte sedimentation rate: 93 mm/h; the other ancillary tests were normal. The patient was referred for neuroimmunological analysis, which revealed intrathecal synthesis for the three largest immunoglobulins as a synthesis pattern, without any impairment of the blood/CSF barrier, concluding that this was an inflammatory process of the CNS (Fig. 2, reibergram 2).

Due to the clinical symptoms of the patient, the results from the ancillary tests and the background of NB, this was interpreted as



Reibergram areas:

1. There is no intrathecal synthesis
2. Impairment of barrier with no intrathecal synthesis
3. Intrathecal synthesis without barrier impairment
4. Intrathecal synthesis with barrier impairment
5. No biological significance (analytical error)

Figure 1. Reibergram and its areas.

an exacerbation or outbreak of the disease. Treatment was administered with methylprednisolone.

Discussion

CSF studies in patients with NB have reported the increase in pro-inflammatory cytokines, particularly interleukin 6, which is characteristic of the active phase of the illness, playing a major role in the processes of neuronal damage and neuroapoptosis.^{6,7}

Secondary to the autoimmune processes in Behçet's disease, we find the deposit of immunoglobulins, demonstrated by immunofluorescence. Of these, the endothelial anticellular, anti-kinectin and antinuclear antibodies are the ones with a key function in the physiopathology of this vasculitis and are one of the causes of tissue damage.^{6–8}

This patient presented with a pattern of intrathecal synthesis for the three classes of immunoglobulins in both exacerbations of the disease. However, there was no dysfunction of the blood/CSF barrier.

We suggest that this barrier is highly relevant, since it not only limits access of circulating molecules towards the brain, but also limits access towards the brain of antigens from the systemic immune system.⁹

The latter is an indicator of complete disease remission and this corresponded with the course of this disease in our clinical case patient.

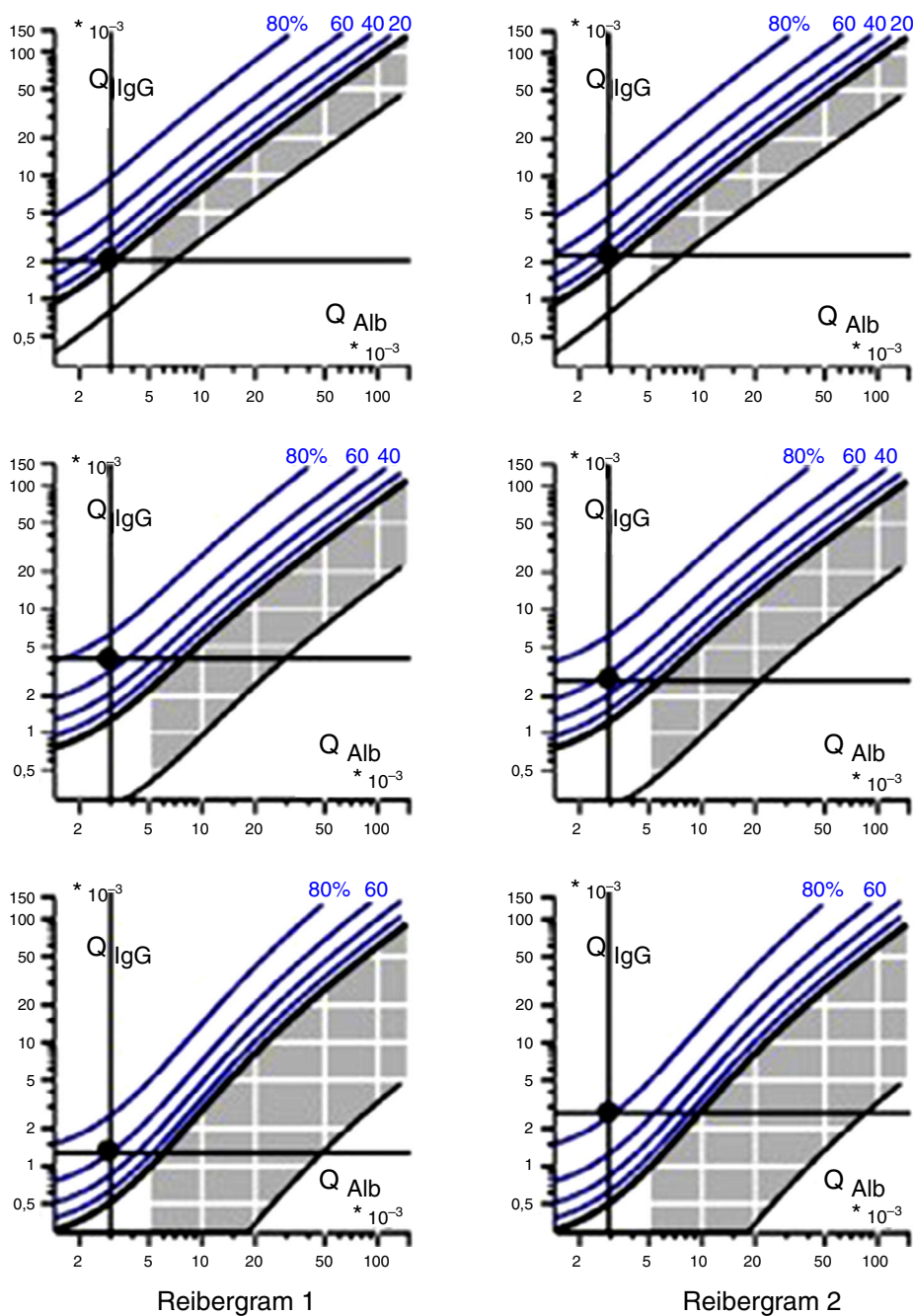


Figure 2. Reibergrams of the patient.

Conclusions

The findings from this case are the first study where the Reibergram was used to assess the neuro-immunological response in a patient with NB, and its use may therefore be indicated for the active phase of the disease.

Ethical Liabilities

Protection of people and animals. The authors declare that the procedures followed comply with the ethical standards of the Committee responsible for human experimentation and are in

keeping with the World Medical Association and the Declaration of Helsinki.

Data confidentiality. The authors declare they have followed the protocols of their centre of work on patient data publication.

Right to privacy and informed consent. The authors declare that no patient data appear in this article.

Conflict of Interests

The authors have no conflict of interests to declare with regard to this article.

References

1. Castillo González W, González-Argote J, Hernández Estévez J. Enfermedad de Behçet. *Rev Cuba Reumatol.* 2014;16:309–21.
2. Davatchi F, Assaad-Khalil S, Calamia KT, Crook JE, Sadeghi-Abdollahi B, Schirmer M, et al. The International Criteria for Behçet's Disease (ICBD): A collaborative study of 27 countries on the sensitivity and specificity of the new criteria. *J Eur Acad Dermatol Venereol.* 2014;28:338–47, <http://dx.doi.org/10.1111/jdv.12107>.
3. García-Rivero AA, Gonzalez-Argote J, Martínez Larrarte JP. Neurobehçet. *Rev Cuba Reumatol.* 2015;17:222–33.
4. Reiber H. Cerebrospinal fluid data compilation and knowledge-based interpretation of bacterial, viral, parasitic, oncological, chronic inflammatory and demyelinating diseases. Diagnostic patterns not to be missed in neurology and psychiatry. *Arq Neuropsiquiatr.* 2016;74:337–50, <http://dx.doi.org/10.1590/0004-282X20160044>.
5. Dorta-Contreras AJ, Reiber H, Noris García E, Padilla Docal B, Bu Cofiu Fanego R, Robinson Agramonte MA. *Neuroinmunología básica.* La Habana: Academia; 2007.
6. Lopalco G, Lucherini OM, Vitale A, Talarico R, Lopalco A, Galeazzi M, et al. Putative role of serum amyloid-A and proinflammatory cytokines as biomarkers for Behçet's disease. *Medicine (Baltimore).* 2015;94:e1858, <http://dx.doi.org/10.1097/MD.0000000000001858>.
7. Lee JS, Park MJ, Park S, Lee ES. Differential expression of T cell immunoglobulin- and mucin-domain-containing molecule-3 (TIM-3) according to activity of Behçet's disease. *J Dermatol Sci.* 2012;65:220–2.
8. Hirohata S, Kikuchi H. Changes in biomarkers focused on differences in disease course or treatment in patients with neuro-Behçet's disease. *Intern Med.* 2012;51:3359–65.
9. Hirohata S, Takeuchi A, Miyamoto T. Association of cerebrospinal fluid IgM index with central nervous system involvement in Behçet's disease. *Arthritis Rheum.* 1986;29:793–6.