

Table 1

Median Nerve Area (MNA) and Median Nerve Perimeter (MNP) comparison between the 3 phases of skin involvement among Systemic Sclerosis patients.

	Edematous (n=22)	Fibrotic (n=24)	Atrophic (n=2)	p value
Median MNA (mm ²)	9.25 [7.5 to 11.5]	7.25 [6.5 to 8.4]	7.25	<0.05
Median MNP (mm ²)	14.5 [13.5 to 16.9]	13.4 [12.4 to 13.9]	12.8	<0.05

between mRSS and both MNA (Spearman's rho=0.335, p=0.02) and MNP values (rho=0.336, p=0.02). There was no correlation between MN US parameters and age, disease duration, HAMIS or SScSS. MNA and MNP were also similar in relation to gender and subset of disease (p>0.05). However, median of MNA and MNP were significantly different between the 3 phases of skin involvement, being higher in patients in the edematous phase (Table 1).

Our study showed an increased MNA and MNP in SSc patients in comparison with controls while few data available from previous studies yielded mixed results^{3–5}. Contrarily to Bandinelli F et al³ who did not find any correlation between MN US measurements and SSc clinical features, we found some interesting correlations. In our study, patients in the edematous phase of skin involvement and patients with higher skin thickness assessed by mRSS showed higher MNA and MNP values. The presence of tissue edema and thick skin may contribute as mechanical factors for MN entrapment in the CT. Larger studies are needed to draw definite conclusions.

References

1. Amaral TN, Peres FA, Lapa AT, Marques-Neto JF, Appenzeller S. Neurologic involvement in scleroderma: A systematic review. *Semin Arthritis Rheum.* 2013;43:335–47.
2. Morer IC, Marco JV, Aznar JLH, Lafita CA, Caballo RB, Juste AO. Manifestaciones neurológicas en la esclerosis sistémica. *Rev Clin Esp.* 2003;203:373–7.
3. Bandinelli F, Kaloudi O, Candelieri A, Conforti ML, Casale R, Cammarata S, et al. Early detection of median nerve syndrome at the carpal tunnel with high-resolution 18MHz ultrasonography in systemic sclerosis patients. *Clin Exp Rheumatol.* 2010;28:15–8.
4. Bignotti B, Ghio M, Panico N, Tagliafico G, Martinoli C, Tagliafico A. High-resolution ultrasound of peripheral nerves in systemic sclerosis: a pilot study of computer-aided quantitative assessment of nerve density. *Skeletal Radiol.* 2015;44:1761–7.
5. Tagliafico A, Panico N, Resmini E, Derchi LE, Ghio M, Martinoli C. The role of ultrasound imaging in the evaluation of peripheral nerve in systemic sclerosis (scleroderma). *Eur J Radiol.* 2011;77:377–82.

Joana Sousa-Neves,* Marcos Cerqueira, Carmo Afonso, Filipa Teixeira

Rheumatology Department, Conde de Bertandos Hospital, Ponte de Lima, Portugal

* Corresponding author.

E-mail address: joanasvsneves@gmail.com (J. Sousa-Neves).

2173-5743/

© 2017 Elsevier España, S.L.U. and Sociedad Española de Reumatología y Colegio Mexicano de Reumatología. All rights reserved.

Edema and Dermatomyositis. Migratory Edema and Edematous and Vesiculobullous Dermatomyositis Overlap*



Edema y dermatomiositis. Edema migratorio y solapamiento de dermatomiositis edematosa y vesiculoampollosa

To the Editor,

Extrafacial edema is a rare manifestation of dermatomyositis (DM). We report 2 cases.

Case no. 1. The patient was an 86-year-old woman who was admitted with dysphagia, dyspnea, weakness in her 4 extremities (2/5) and edemas. Four years earlier, she had been diagnosed with cryptogenic organizing pneumonia detected by means of pulmonary function tests, imaging studies and histology. It was observed that, aside from periorbital edema, she had edema with fovea in upper and lower limbs. She had plaques with vesiculobullous eruption on her forearms and erythematous and edematous eruption on her thighs (Fig. 1). Biopsy of the thigh revealed epidermal atrophy, subepidermal bullous disease, necrotic keratinocytes, superficial perivascular infiltrate, mucin and dermal edema. Direct immunofluorescence was negative, as were tests for anti-Jo-1, anti-PL7, anti-PL12, anti-SRP-54, anti-Mi2, anti-Ku and anti-PM/Scl antibodies. Creatine kinase (CK) was 1267 U/L. Electromyogram demonstrated the myopathic changes and muscle biopsy revealed perifascicular atrophy and CD4+ perimysium and perivascular inflammatory infiltrate.

A cardiac origin of the edema was ruled out, as were renal, hepatic and thyroid origin. Albumin, after multiple hospital admissions for dyspnea, weakness and edemas, had decreased (2.5–3.2 g/dL) and reached normality after treatment with corticosteroids. Having reviewed her history, we finally discovered the diagnosis of her lung disease: an elevated CK level (1370 U/L). Computed tomography revealed a breast lesion that was found to be an infiltrating ductal carcinoma. She was treated with prednisone at a dose of 1 mg/kg body weight (bw)/day and 5 sessions of plasmapheresis. After mastectomy, dysphagia persisted and we detected a diffuse disseminated signet ring cell adenocarcinoma. She died 4 months later due to respiratory failure.

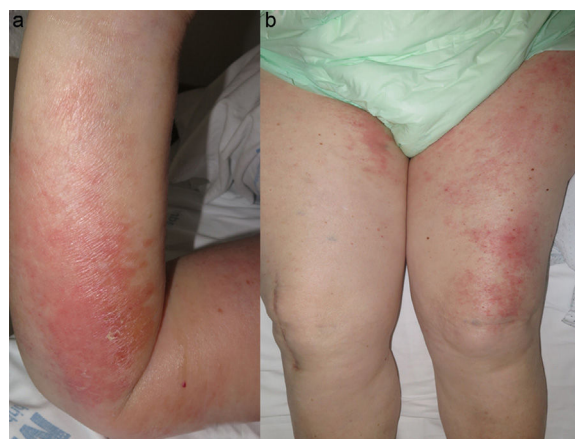


Fig. 1. (a) Erythematous and edematous plaque with superficial vasculobullae in right upper limb. (b) Edema and erythematous and edematous plaques on thighs.

* Please cite this article as: Lozano-Masdemont B, Pulido-Pérez A, Parra-Blanco V, Avilés-Izquierdo JA. Edema y dermatomiositis. Edema migratorio y solapamiento de dermatomiositis edematosa y vesiculoampollosa. *Reumatol Clin.* 2018;14:313–314.

Case no. 2. The patient was a 71-year-old man who had been treated 7 months earlier for cancer of the cavum. He presented with weakness of his upper (2/5) and lower (3/5) limbs, skin lesions and migratory swelling; it began in his neck and supraclavicular region, followed by ankles, abdomen and upper limbs. Other causes of edema were ruled out. His CK level was 728 U/L and the same antibody panel was negative. Electromyogram and muscle biopsy were similar to those of case no. 1. A week with prednisone at a dose of 1 mg/kg bw/day, resolved the edema; treatment was increased with methotrexate at 20 mg/week, but he died 7 months later due to muscular respiratory failure.

Edematous DM^{1–5} could constitute up to 6% of the cases of DM.¹ It is characterized by extrafacial, localized or generalized edema, with or without fovea, with no other cause of edema. It is more prevalent in women (2:1), of ages between 23 and 93 years. The diagnostic delay is more than 2 months.² It is speculated that it is originated by ischemia of the microvasculature. To date, the migratory localization so characteristic of our case had not been reported. Vesiculobullous DM consists of subepidermal vesiculobullae with biopsy results typical of DM, with no other bullous dermatosis. Its cause has been proposed to be friction, dermal edema and mucin. The specimen for the biopsy in the first case was taken from the patient's thigh, where no clinical detachment was observed. We subsequently considered that the detachment was secondary to the edema and that the two clinical forms, edematous and vesiculobullous, could be the same manifestation or overlap. The distribution does not indicate a mechanical cause and there are similar cases of severe edema in which detachment appeared.^{5–7}

The cause of hypoalbuminemia of the first case was due to the proinflammatory status of the interstitial lung disease and the DM that still had not been diagnosed.^{8,9} This hypoalbuminemia could be the cause of generalized edema, but not of the erythematous and edematous and vesiculobullous plaques. The literature demonstrates that edematous DM could be associated with a more severe myopathy and dysphagia, a finding that was not observed in our patients.^{1–3} Likewise, vesiculobullous DM would be closely associated with neoplasms and a worse prognosis.^{6,10} Extrafacial edema in DM, in any of its variants should alert physicians to a greater severity and lead to an active search for a neoplasm.

References

- Milisenca JC, Doti PI, Prieto-González S, Grau JM. Dermatomyositis presenting with severe subcutaneous edema: five additional cases and review of the literature. *Semin Arthritis Rheum.* 2014;44:228–33.
- Goussot R, Wettlé C, le Coz C, Cribier B, Lipsker D. Severe edematous dermatomyositis. *Ann Dermatol Venereol.* 2016;143:202–9.
- Chai Y, Bertorini TE, Li YD, Mitchell C, Guan H. Limb edema and anasarca associated with severe dermatomyositis: report of four cases. *Neuromuscul Disord.* 2011;21:439–42.
- Jung KD, Kim PS, Park HY, Kim CR, Byun JY, Lee DY, et al. Dermatomyositis associated with generalized subcutaneous edema and Evans syndrome. *J Am Acad Dermatol.* 2012;66:144–7.
- Watanabe M, Natsuga K, Arita K, Abe R, Shimizu H. Generalized acute subcutaneous edema as a rare cutaneous manifestation of severe dermatomyositis. *J Eur Acad Dermatol Venereol.* 2016;30:e151–2.
- Mitsuya J, Hara H, Hattori A, Matsunaga A, Terui T. Vesicle formation in dermatomyositis associated with colon carcinoma. *Clin Exp Dermatol.* 2009;34:e221–2.
- Nishigori K, Yamamoto T, Yokozeki H. Vesiculo-bullous dermatomyositis: report of three cases. *Dermatol Online J.* 2009;15:6.
- Bohan A, Peter JB. Polymyositis and dermatomyositis (first of two parts). *N Engl J Med.* 1975;292:344–7.
- Bohan A, Peter JB. Polymyositis and dermatomyositis (second of two parts). *N Engl J Med.* 1975;292:403–7.
- Kubo M, Sato S, Kitahara H, Tsuchida T, Tamaki K. Vesicle formation in dermatomyositis associated with gynecologic malignancies. *J Am Acad Dermatol.* 1996;34:391–4.

Belén Lozano-Masdemont,^{a,*} Ana Pulido-Pérez,^a
Verónica Parra-Blanco,^b José Antonio Avilés-Izquierdo^a

^a Servicio de Dermatología, Hospital General Universitario Gregorio Marañón, Madrid, Spain

^b Servicio de Anatomía Patológica, Hospital General Universitario Gregorio Marañón, Madrid, Spain

* Corresponding author.

E-mail address: belenmasdemont@gmail.com
(B. Lozano-Masdemont).

2173-5743/

© 2017 Elsevier España, S.L.U. and Sociedad Española de Reumatología y Colegio Mexicano de Reumatología. All rights reserved.

Rice Bodies in Tuberculous Tenosynovitis of Wrist



Cuerpos de arroz en la tenosinovitis tuberculosa de la muñeca

Dear Editor,

Rice body formation is an uncommon inflammatory process occurring in joints and tendon sheaths in systemic disorders.¹ Since their first description in 1895 in a patient with tuberculosis, these have been described in various rheumatic diseases including rheumatoid arthritis, juvenile idiopathic arthritis, and seronegative inflammatory arthritis, in infections with atypical mycobacteria, and in subacromial bursitis.^{2–5} Generally involving shoulder and knee joints, we describe here a rare case report of a patient with isolated wrist tenosynovitis with rice bodies on magnetic resonance imaging (MRI) who was diagnosed as tuberculosis based on results of microbiologic investigations.

A 50-year-old lady came with progressive pain and isolated swelling of the right wrist of 9 months duration. Physical examination revealed an oblong swelling on the volar aspect of wrist

extending into the forearm. Attempted active flexion at the wrist was painful though passive range of movement was normal. Laboratory investigations showed raised erythrocyte sedimentation rate of 50 mm/h. Radiograph of the wrist was normal. MRI revealed well-defined fluid intensity collection along the flexor tendon sheath with presence of hypointense-layered lucencies within suggestive of tenosynovitis with rice bodies (Fig. 1A and B). The adjacent bone and soft tissues were normal. Fluid obtained by ultrasound-guided aspiration from the tenosynovial swelling was positive for Acid Fast Bacilli. Culture grew *Mycobacterium Tuberculosis* and hence, diagnosis of tuberculosis was reached. The patient did not have diabetes and was not on any immunosuppressive drugs. Serology for Human Immunodeficiency Virus (HIV) was non-reactive. The patient responded to six months of anti-tuberculous therapy with complete resolution of pain and swelling.

Rice bodies are called so due to their resemblance to grains of polished white rice on gross examination. The pathogenesis of rice body formation is unclear, but is likely related to shedding of the infarcted synovial tissue into the joint.² These are formed by fibrin deposits on a nidus of sloughed synovium or inflamed tissue, as