




Sociedad Española  
de Reumatología -  
Colegio Mexicano  
de Reumatología

# Reumatología Clínica

www.reumatologiaclinica.org



## Letter to the Editor

### Evaluation of a Patient With Temporomandibular Joint Disorders in Paget's Disease of Bone<sup>☆</sup>



#### *Evaluación de un paciente con trastornos de la articulación temporomandibular en la enfermedad ósea de Paget*

Dear Editor,

Paget's disease of bone (PDB) is a chronic process characterised by an increase in bone remodelling.<sup>1</sup> Its clinical presentation varies and may consist of asymptomatic cases detected by an increase in serum levels of alkaline phosphatase (AP) or coincidental radiological findings, or even bone pain and bone deformity.<sup>2</sup>

First line treatment is aimed at reducing pain (NSAIDs, paracetamol, COX-2 inhibitors) and later to reducing the speed of bone turnover (calcitonin and bisphosphonates [BP]).<sup>3</sup>

The aim of this clinical case is to show an unusual presentation in TMJ within the context of a PDB, and also to show what treatment may be followed.

We present the case of a 72-year-old patient who was diagnosed with a monostotic variant of PDB (affecting the ulna) of 5-year duration, which was initially treated with analgesics (NSAIDs, paracetamol, COX-2 inhibitors) and later with oral alendronate at a dose of 40 mg quarterly together with vitamin D (400 U) and Calcium (1.5 g) supplements. The patient was referred to our department suffering from pain (VAS = 7/10) in the right temporomandibular Joint (TMJ) and a reduction of oral opening (<2.5 cm). The examination was completed with computerised axial tomography (CAT) which revealed condylar deformity with osteosclerosis and osteophytes (Fig. 1). The diagnosis made was arthropathy of the TMJ and was initially treated with a jaw release splint, rehabilitation exercises, analgesic treatment and muscle relaxants. Following periodic three-monthly check-ups after a year of treatment a reduction in pain was noted (VAS: 3/10) and an increase in joint function with oral opening above 3 cm.

Involvement of the jawbones and specifically of the TMJ in PDB is a rare occurrence.<sup>4</sup>

Despite not verifying jawbone involvement, and without being able to rule out other causes (osteoarthritis, arthritis), due to the absence of previous events, this case was suggestive of an isolated involvement of the TMJ provoked by continuous stress to which the articular condyles are subjected as a consequence of mastication, leading to degenerative phenomena with episodes of bone remodelling. However, confirmation of this

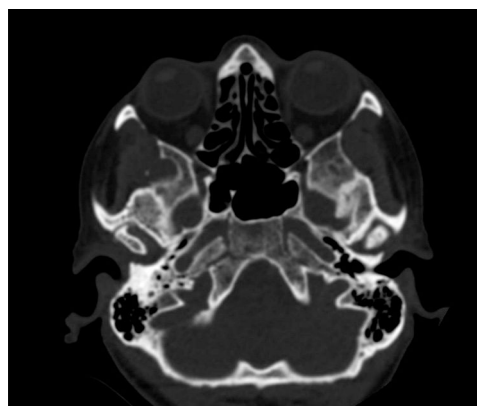

Fig. 1. CT scan showing condylar deformity with osteosclerosis, flattening and osteophytes.

hypothesis would require the undertaking of more specific tests (bone scintigraphy).

Clinical signs of improvement globally appreciated corroborate the current trend<sup>5,6</sup> that treatment with second and third generation BPs (pamidronate, alendronate, risedronate, zoledronate) are more effective than calcitonin and etidronate for serum and degenerative disease control.

### References

- Ralston SH, Langston AL, Reid IR. Pathogenesis and management of Paget's disease of bone. *Lancet*. 2008;372:155–63.
- Whyte MP. Paget's disease of bone. *N Engl J Med*. 2006;355:593–600.
- Alonso N, Calero-Paniagua I, del Pino-Montes J. Clinical and genetic advances in Paget's disease of bone: a review. *Clin Rev Bone Miner Metab*. 2017;15:37–48.
- Badel T, Podoreski D, Kraljevic S, Keros J, Krapac L. Discopathy and osteoarthritis of temporomandibular joint in a patient with Paget disease and osteoporosis. A case report. *Bone*. 2009;44:339–50.
- Singer FR, Bone HG 3rd, Hosking DJ, Lyles KW, Murad MH, Reid IR, et al. Paget's disease of bone: an endocrine society clinical practice guideline. *J Clin Endocrinol Metab*. 2014;99:4408–22.
- Merlotti DL, Gennari G, Martini F, Valleggi V, de Paola A. Comparison of different intravenous bisphosphonate regimens for Paget's disease of bone. *J Bone Miner Res*. 2007;22:1510–7.

José Darío Sánchez López,\* Paolo Cariati,  
Miguel Ángel Pérez de Perceval Tara

*Servicio de Cirugía Oral y Maxilofacial, Hospital Universitario Virgen de las Nieves, Granada, Spain*

\* Corresponding author.

E-mail address: [josed.sanchez.sspa@juntadeandalucia.es](mailto:josed.sanchez.sspa@juntadeandalucia.es)  
(J.D. Sánchez López).

<sup>☆</sup> Please cite this article as: Sánchez López JD, Cariati P, Pérez de Perceval Tara MA. Evaluación de un paciente con trastornos de la articulación temporomandibular en la enfermedad ósea de Paget. *Reumatol Clin*. 2019;15:e74.