



Sociedad Española  
de Reumatología -  
Colegio Mexicano  
de Reumatología

# Reumatología Clínica

www.reumatologiaclinica.org



## Images in Clinical Rheumatology

### Bilateral pathologic mandibular fracture in maxillary osteonecrosis induced by bisphosphonates<sup>☆</sup>

### Fractura patológica mandibular bilateral en osteonecrosis maxilar inducida por bisfosfonatos

Jose Darío Sánchez López,<sup>\*</sup> Paolo Cariati, Miguel Angel Perez de Perveval Tara

Servicio de Cirugía Oral y Maxilofacial, Complejo Hospitalario Universitario de Granada, Granada, Spain

#### ARTICLE INFO

##### Article history:

Received 17 October 2017

Accepted 9 January 2018

Available online 18 May 2019

We present the case of a 75 year old patient with a history of heavy smoking (20 cigarettes per day over 15 years) and poor oral hygiene, diagnosed with advanced EIV (cT4N2bMx) epidermoid cancer of the breast in 2009, who underwent surgery (quadrantectomy and homolateral axillary clearance) with complementary radiotherapy and chemotherapy treatment. On suspicion of the cancer spreading to the bone, treatment with zoledronic acid (Zometa<sup>®</sup>), an intravenous bisphosphonate was initiated, at a dose of 4 mg/3 months until 2014.<sup>1</sup>

In 2015, with no other precipitating factors (for example oral surgery), active intraoral discharge was clinically detected and exposure of the intraoral necrotic bone. Panoramic radiograph was performed which showed bilateral mandibular non displaced fracture (Fig. 1). At the moment, following antibiotic treatment with amoxicillin 1g/8h and daily mouth rinses every 8h with 2% chlorhexidine, clinical evolution has been stable, without any fragment displacement that requires surgery.

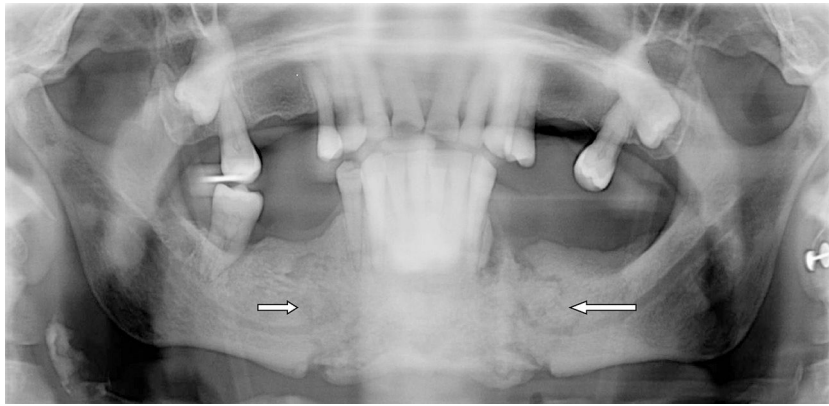
There are many mechanisms of action of bisphosphonates, including: reduction of bone reabsorption due to the inhibition of the osteoclastic activity, induction of apoptosis of osteoclasts, antiangiogenic action and alteration of physiological bone remodelling.<sup>2</sup> These actions on the bone lead to fragility and incapacity for repairing microfractures due to repetitive stress which, associated with terminal irrigation of the lower jaw, turns this area into a region which is liable to suffer osteonecrosis and in exceptional cases, pathological fractures.<sup>3</sup>

There are currently 4 stages to classify mandibular osteonecrosis according to the regulations established by the American Association of Oral and Maxillofacial Surgeons,<sup>4</sup> with our case presented here corresponding to stage four. The case presented appears to prove that individual patient factors, combined with the characteristics of the bisphosphonate used (zoledronic acid), the intravenous administration and prolonged administration, as well as its high potency,<sup>5,6</sup> were the predisposing factors for the appearance of massive osteonecrosis of the jaw.

<sup>☆</sup> Please cite this article as: Sánchez López JD, Cariati P, Perez de Perveval Tara MA. Fractura patológica mandibular bilateral en osteonecrosis maxilar inducida por bisfosfonatos. Reumatol Clin. 2020;16:62–63.

<sup>\*</sup> Corresponding author.

E-mail address: [josed.sanchez.sspa@juntadeandalucia.es](mailto:josed.sanchez.sspa@juntadeandalucia.es) (J.D. Sánchez López).



**Fig. 1.** Image showing the bilateral fracture of the jaw in a mandibular osteonecrosis induced by biphosphonate (the 2 arrows mark the fracture lines).

### Conflict of interests

The authors have no conflict of interests to declare.

### References

1. Dhesy-Thind S, Fletcher GG, Blanchette PS, Clemons MJ, Dillmon MS, Frank ES, et al. Use of adjuvant bisphosphonates and other bone-modifying agents in breast cancer: a Cancer Care Ontario and American Society of Clinical Oncology clinical practice guideline. *J Clin Oncol.* 2017;35:2062–81.
2. Nakano T, Yamamoto M, Hashimoto J, Tobinai M, Yoshida S, Nakamura T. Higher response with bone mineral density increase with monthly injectable ibandronate 1 mg compared with oral risedronate in the MOVER study. *J Bone Miner Metab.* 2016;34:678–84.
3. Mücke T, Krestan CR, Mitchell DA, Kirschke JS, Wutzl A. Bisphosphonate and medication-related osteonecrosis of the jaw: a review. *Semin Musculoskelet Radiol.* 2016;20:305–14.
4. Ruggiero S, Dodson T, Fantasia J, Goodday R, Aghaloo T, Mehrotra B, et al. American Association of Oral and Maxillofacial Surgeons position paper on medication-related osteonecrosis of the jaw-2014 update. *J Oral Maxillofac Surg.* 2014;72:1938–56.
5. Bagan L, Jiménez Y, Leopoldo M, Murillo-Cortes J, Bagan J. Exposed necrotic bone in 183 patients with bisphosphonate-related osteonecrosis of the jaw: associated clinical characteristics. *Med Oral Patol Oral Cir Bucal.* 2017;22:e582–5.
6. Manfredi M, Mergoni G, Goldoni M, Salvagni S, Merigo E, Meleti M, et al. A 5-year retrospective longitudinal study on the incidence and the risk factors of osteonecrosis of the jaws in patients treated with zoledronic acid for bone metastases from solid tumors. *Med Oral Patol Oral Cir Bucal.* 2017;22:e342–8.