



Sociedad Española  
de Reumatología -  
Colegio Mexicano  
de Reumatología



## Images in Clinical Rheumatology

### A man with Garrod's pads and camptodactyly<sup>☆</sup>

### Varón con nódulos de Garrod y camptodactilia

Carolina Diez Morrondo,\* Lucía Pantoja Zarza

Servicio de Reumatología, Hospital El Bierzo, Ponferrada, León, Spain

#### ARTICLE INFO

##### Article history:

Received 20 December 2017

Accepted 15 January 2018

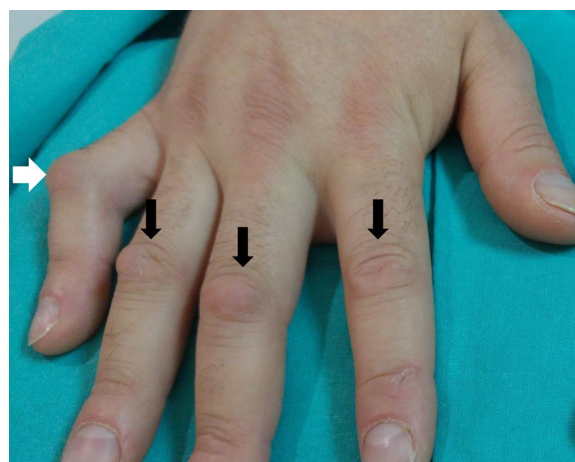
Available online 23 May 2019

#### Clinical case

We present the case of a 40-year-old male with no other personal or family history of interest who consulted with a 3-year history of nodules of a soft consistency on the dorsal surface of the proximal interphalangeal joints (PIPJ) of both hands (Fig. 1). He reported no pain or restricted mobility; physical examination did not reveal synovitis. Our attention was drawn to a proximal interphalangeal joint flexion contracture of the fifth finger of the right hand (Fig. 1). The dermatology department was consulted, and the clinical suspicion of Garrod pads was confirmed. We decided not to prescribe any treatment because these are asymptomatic lesions.

#### Discussion

Knuckle or Garrod pads are a type of digital fibromatosis characterised as asymptomatic papular or nodular lesions seated on the dorsal surface of the PIPJ or, less often, the metacarpophalangeal joints.<sup>1–4</sup> Since they can be confused with synovitis, it is important for the rheumatologist to be aware of them.<sup>1,4</sup> Their aetiology is usually idiopathic or relating to repeated trauma.<sup>1,3</sup> They can be hereditary, and associated with autosomal dominant hereditary diseases such as Peyronie's disease, Bart–Pumphrey syndrome or Dupuytren's disease.<sup>1,3</sup> Likewise, such as the patient in this study, Garrod pads have been described in combination with camptodactyly (flexion contracture of a finger, usually the fifth digit).<sup>4–7</sup> When this association presents, associated genetic syndromes should be discounted.<sup>5–8</sup> We would also highlight that camptodactyly has been described associated with arthritis and



**Fig. 1.** Painless nodules of a soft consistency on the back of the proximal interphalangeal joints of the hand, termed Garrod pads (black arrows). In addition to the Garrod pads a proximal interphalangeal joint flexion contracture of the fifth finger can be seen, known as camptodactyly (white arrow). When this association presents, associated genetic syndromes should be ruled out. Likewise, we should remember that camptodactyly has been described associated with arthritis and constrictive pericarditis.

constrictive pericarditis.<sup>8</sup> Although diagnosis is usually clinical, histological study will reveal epidermal hyperplasia with hyperkeratosis, fibroblastic proliferation, and absence of inflammatory infiltrate.<sup>1,3</sup> With regard to treatment, given the benign nature of the condition, many authors advocate therapeutic abstention.<sup>1</sup> Nevertheless, in some cases topical glucocorticoids and keratolytic agents have been used, and even surgical removal.<sup>1,3</sup>

#### Conflict of interests

The authors have no conflict of interests to declare.

<sup>☆</sup> Please cite this article as: Diez Morrondo C, Pantoja Zarza L. Varón con nódulos de Garrod y camptodactilia. Reumatol Clin. 2020;16:185–186.

\* Corresponding author.

E-mail address: [caroldiez81@hotmail.com](mailto:caroldiez81@hotmail.com) (C. Diez Morrondo).

## References

1. Rodríguez-Muguruza S, Riveros A, Sanint J, Olivé A. Nódulos de Garrod. *Semin Fund Esp Reumatol.* 2013;14:91–3.
2. Nenoff P, Woitek G. Images in clinical medicine. Knuckle pads. *N Engl J Med.* 2011;364:2451.
3. Hyman CH, Cohen PR. Report of a family with idiopathic knuckle pads and review of idiopathic and disease-associated knuckle pads. *Dermatol Online J.* 2013;19:18177.
4. Tamborrini G, Gengenbacher M, Bianchi S. Knuckle pads. A rare finding. *J Ultrason.* 2012;12:493–8.
5. Du ZF, Wei W, Wang YF, Chen XL, Chen CY, Liu WT, et al. A novel mutation within the 2B rod domain of keratin 9 in a Chinese pedigree with epidermolytic palmoplantar keratoderma combined with knuckle pads and camptodactyly. *Eur J Dermatol.* 2011;21:675–9.
6. Malik S, Schott J, Schiller J, Junge A, Baum E, Koch MC. Fifth finger camptodactyly maps to chromosome 3q11.2–q13.12 in a large German kindred. *Eur J Hum Genet.* 2008;16:265–9.
7. Corbo MD, Weinstein M. Camptodactyly and knuckle pads coexisting in an adolescent boy: connection or coincidence? *Pediatr Dermatol.* 2015;32:126–7.
8. Martínez-Lavín M, Buendía A, Delgado E, Reyes P, Amigo MC, Sabanés J, et al. A familial syndrome of pericarditis, arthritis, and camptodactyly. *N Engl J Med.* 1983;309:224–5.