

- Shibuya N, la Fontaine J, Frania SJ. Alcohol-induced neuroarthropathy in the foot: a case series and review of literature. *J Foot Ankle Surg.* 2008;47:118–24.
- Kucera T, Shaikh HH, Sponer P. Charcot neuropathic arthropathy of the foot: a literature review and single-center experience. *J Diabetes Res.* 2016;2016:3207043.
- Schneekloth BJ, Lowery NJ, Wukich DK. Charcot neuroarthropathy in patients with diabetes: an updated systematic review of surgical management. *J Foot Ankle Surg.* 2016;55:586–90.

Rami Qanneta,\* Elisa Bové Aleu

Hospital Sociosanitario Francolí, Tarragona, Spain

\*Corresponding author.

E-mail address: rami\_kanita229@hotmail.com (R. Qanneta).

<https://doi.org/10.1016/j.reumae.2018.01.013>

2173-5743/ © 2018 Elsevier España, S.L.U. and Sociedad Española de Reumatología y Colegio Mexicano de Reumatología. All rights reserved.

## Distal intersection syndrome: An unusual cause of forearm pain<sup>☆</sup>



### Síndrome de la intersección distal. Una causa poco frecuente de dolor en el antebrazo

Dear Editor,

Pain in the carpus and forearm is a frequent reason for rheumatology consultation. Overuse tendonitis and repeated microtrauma are among the most frequent mechanical causes. De Quervain's tendonitis is one of the most common conditions, although there are also other less common disorders with a similar clinical presentation.

We present the case of a 28-year-old woman, with no clinical history of interest, who consulted due to the sudden onset of pain and swelling on the dorsal surface of the distal third of her right forearm with marked functional limitation on extension of the carpus and first finger. The patient is an administrative worker, whose only recent history of note was having rowed during her recent holidays. Examination revealed local heat and swelling on the dorsolateral region of the forearm around 5 cm proximal to the radiocarpal joint. On resisted extension of the first finger, the patient's pain increased, and there was marked crepitus at this level. Finkelstein's manoeuvre was positive, painful at around 5 cm proximal to the radiocarpal joint. Sensory examination was normal. The patient had no synovitis or pain in other areas.

An ultrasound was performed (Image 1) showing tenosynovitis of the 2 tendons of the I extensor compartment (short extensor and long abductor of the thumb) at the level of the distal third of the forearm as it crosses the tendons of the II dorsal compartment, with no power Doppler signal. Joint measurements of the AL + ECRL, and EB + extensor tendons were taken, .38 and .41 cm<sup>2</sup> respectively, which are above the measurements usually described.<sup>1</sup> There was no tendon involvement at the level of the radial styloid. Ultrasound of the carpus and forearm of the healthy side was normal. Distal intersection syndrome caused by rowing was diagnosed. The patient was treated with rest and immobilisation for a week, and ultrasound-guided injection of 40 mg of triamcinolone acetonide. After 2 weeks she showed full clinical and ultrasound improvement.

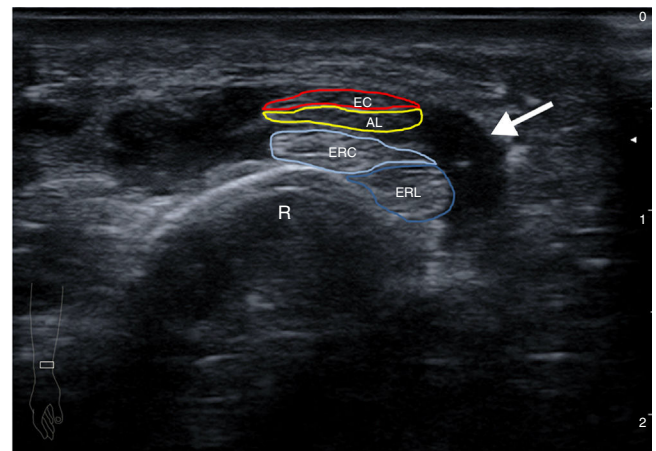
Distal intersection syndrome is caused by mechanical rubbing between the long abductor and short extensor tendons of the thumb and the tendons of the radial carpal extensors (short and

long) that are beneath the 2 former.<sup>2</sup> The 4 tendons intersect forming a 30° angle at about 4–5 cm from the radiocarpal joint (Image 2). The main cause of inflammation at this level is rubbing due to overuse through work (typing or carpentry) or sport (golf, rowing and racquet sports) due to repeated flexion and extension of the wrist.<sup>3,4</sup>

Diagnosis is usually clinical, depending on the site of the pain and crepitus, and ultrasound can be used to confirm findings of tenosynovitis.<sup>5,6</sup> Differential diagnosis must be established with De Quervain's tenosynovitis, Wartenberg syndrome (compressive neuropathy of the superficial sensory branch of the radial nerve) and common extensor tendonitis.<sup>7</sup> Finkelstein's manoeuvre can be positive, but the determining finding for diagnosis is the painful area being located at around 5 cm from the radiocarpal joint (Image 2).

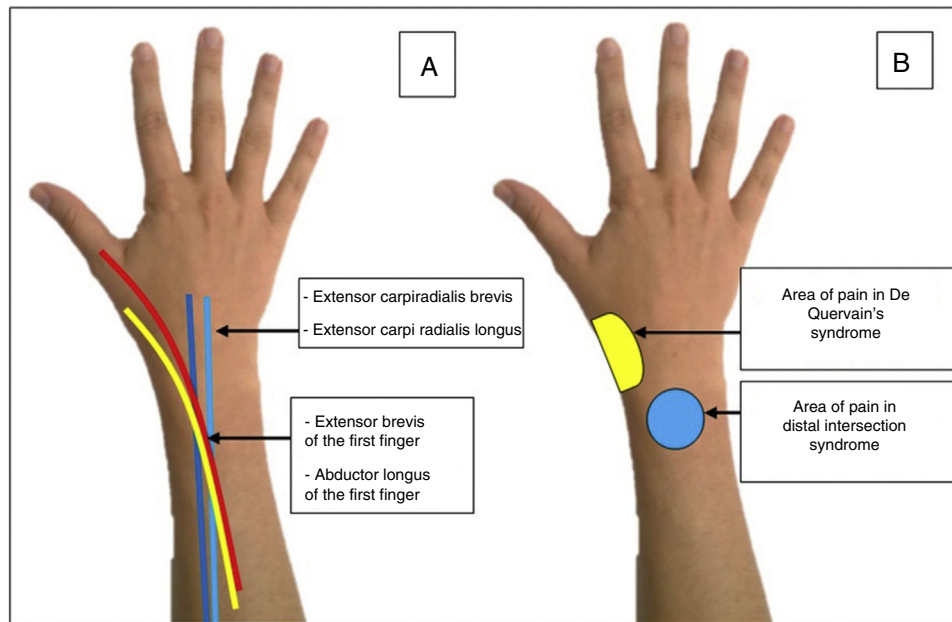
Treatment is based on the local application of cold, rest with anti-inflammatory drugs, and local injections are often very useful for severe or recurring cases. Surgical treatment to release the II extensor compartment might be necessary for cases that are limiting associated with sports activities.

In sum, distal intersection syndrome should be considered in the differential diagnosis of De Quervain's tenosynovitis of atypical presentation, the location of the most medial and proximal pain, and the presence of crepitus are the key to diagnosis.



**Image 1.** Transverse ultrasound image of the distal region of the right forearm. Showing tenosynovitis (arrow) of the tendons of the I and II extensor compartment as they cross. AL: abductor longus of the first finger; EB: extensor brevis of the first finger; ECRB: extensor carpi radialis brevis; ECRL: extensor carpi radialis longus; R: radius.

<sup>☆</sup> Please cite this article as: Pijoán Moratalla C, Blanco Caceres BA, Bachiller Corral J. Síndrome de la intersección distal. Una causa poco frecuente de dolor en el antebrazo. *Reumatol Clin.* 2020;16:128–129.



**Image 2.** (A) Anatomical path of the tendons involved in distal intersection syndrome. (B) Site of pain in distal intersection syndrome and in De Quervain's tendonitis.

### Conflict of interests

The authors have no conflict of interests to declare.

### References

- Christiaan E, Jager T, Lenchik L. Thickness of extensor tendons at the proximal intersection: sonographic measurements in asymptomatic volunteers. *J Ultrasound Med.* 2014;33:2099–103.
- Bianchi S, Martinoli C. Muñeca. In: Bianchi S, Martinoli C, editors. *Ecografía musculoesquelética*. Marban: Springer; 2014. p. 382–449.
- O'Connor PJ. Hand and wrist injuries. In: Robinson P, editor. *Essential radiology for sports medicine*. Leeds: Springer; 2010. p. 143–72.
- McCarthy C. Disorders of the wrist: radial. In: McNally E, editor. *Practical musculoskeletal ultrasound*. Churchill-Livingstone: Elsevier; 2014. p. 113–21.
- Montechiarello S, Miozzi F, D'Ambrosio I, Giovagnorio F. The intersection syndrome: ultrasound findings and their diagnostic value. *J Ultrasound.* 2010;13:70–3.
- De Maeseneer M, Marcelis S, Jager T, Girard C, Gest T, Jamadar D. Spectrum of normal and pathologic findings in the region of the first extensor compartment of the wrist: sonographic findings and correlations with dissections. *J Ultrasound Med.* 2009;28:779–86.
- Hanlon D, Luellen J. Intersection syndrome. A case report and review of the literature. *J Emerg Med.* 1999;17:969–71.

Cristina Pijoán Moratalla,<sup>a,\*</sup> Boris Anthony Blanco Caceres,<sup>b</sup> Javier Bachiller Corral<sup>a</sup>

<sup>a</sup> Servicio de Reumatología, Hospital Universitario Ramón y Cajal, Madrid, Spain

<sup>b</sup> Servicio de Reumatología, Hospital Universitario de Cruces, Baracaldo, Vizcaya, Spain

\* Corresponding author.

E-mail address: [crispimoratalla@gmail.com](mailto:crispimoratalla@gmail.com) (C. Pijoán Moratalla).

<https://doi.org/10.1016/j.reumae.2018.02.002>

2173-5743/ © 2018 Elsevier España, S.L.U. and Sociedad Española de Reumatología y Colegio Mexicano de Reumatología. All rights reserved.