




Sociedad Española  
de Reumatología -  
Colegio Mexicano  
de Reumatología

# Reumatología Clínica

[www.reumatologiaclinica.org](http://www.reumatologiaclinica.org)



## Letter to the Editor

### Bibliography unavailable<sup>☆</sup>



### Bibliografía inaccesible

Dear Editor,

Nobody disputes that bibliographic references are essential to any scientific article: they support what the author has to say, they enable the reader to find the bases for any data of interest to their own studies, they endorse appreciation of the contemporariness of the study and the breadth of the areas underpinning its publication.

However, searching for a bibliographical reference is not usually easy. We cannot always access all journals, some journals disappear, the authors are difficult to contact, and references cannot therefore be directly requested.

Lately this difficulty has increased due to the web page links provided: the speed with which the web alters suggests that these bibliographical references will be hard to locate in upcoming years.

To determine whether this supposition was real I reviewed the bibliographical references of the first 3 issues (one quarter) of 2018 and of the same issues of the year 2007. I noted the number of links cited and how many of them were still available.

In the first 3 issues of volume 3 in 2007 663 bibliographical references were made, of which only 4 (.6%) were links to web sites and only one is attainable.

Between the 2018 January–March–May issues (Vol. 14–2018) there were 957 references, 36 (3.8%) of which referred to web pages. Of these, 22 (61%) are attainable and 14 (39%) no longer are. These

data offers us double confirmation: references to web pages are on the up and it is difficult to gain access to many of these web pages.

All of the above has led me to review the publication regulations which your publishing house establishes for its authors. I have been able to confirm that the journal itself defaults in its instructions to its authors. It explains how the format of a reference to a web page should be with an example using this link, which is no longer active: <http://www.cancerresearchuk.org/aboutcancer/statistics/cancerstatsreport/>.<sup>1</sup>

I propose 2 steps as a solution to this problem: (1) request that the proofreaders be stricter with regards to this important publishing issue, checking that each one of the references is attainable when the article is sent to the editorial board and (2) that the publishers request a PDF copy from the authors of the referenced web sites and that these be stored with the publication documentation, because the persistence of the link and the author's contact details cannot be guaranteed.

### Reference

1. Reumatol Clín. Guía para autores: Formato de las referencias. Available from: <http://www.reumatologiaclinica.org/es/guia-autores/#71000> [accessed 20.06.18].

Cayetano Alegre de Miquel

Servicio de Reumatología, Hospital Universitari Dexeus-Quirón,  
Barcelona, Spain

E-mail address: [11120cam@comb.cat](mailto:11120cam@comb.cat)

<https://doi.org/10.1016/j.reumae.2018.07.005>

2173-5743/ © 2018 Elsevier España, S.L.U. and Sociedad Española de Reumatología y Colegio Mexicano de Reumatología. All rights reserved.

<sup>☆</sup> Please cite this article as: Alegre de Miquel C. Bibliografía inaccesible. Reumatol Clin. 2020;16:368–368.

### Treatment with rituximab in juvenile dermatomyositis: Effect on calcinosis<sup>☆</sup>



### Tratamiento con rituximab en dermatomiositis juvenil. Efecto sobre la calcinosis

Dear Editor,

We describe below the case of a patient with juvenile dermatomyositis, with extensive calcinosis which was refractory to standard treatment and which improved with the use of rituximab.

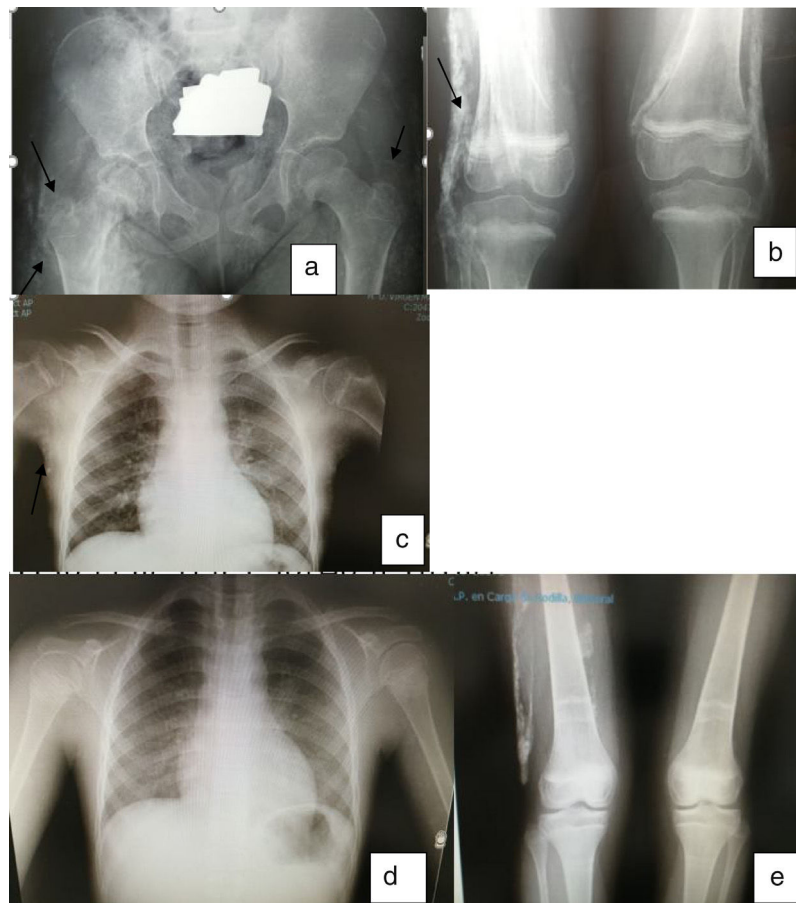
Calcinosis distinguishes juvenile dermatomyositis from the adult disease, of unknown pathogenesis. The deposit of calcium hydroxyapatite and phosphates in soft tissues with normal calciums form part of the inflammatory process of this disease, where the release of mediators such as interleukin 1 beta, interleukin 6 and anti-TNF alpha appear to play a role.<sup>1</sup>

Calcinosis occurs in 10%–70% of cases of juvenile dermatomyositis, heightening morbimortality. It usually presents between 1 and 3 years after diagnosis, but on occasions may appear at the beginning and on others 20 years later. Calcium deposits may appear on the skin, subcutaneous tissues, fascias or tendons, and may even form an exoskeleton in the severest of cases.<sup>1</sup> Intensive fast treatment at the beginning of the disease with complete control of the inflammation can minimise the appearance of calcinosis.<sup>2</sup>

Our case was a 6 year old girl who had been previously healthy, who presented at the paediatric department at the beginning of 2009 with myalgias, abdominal pain and difficulty walking. The following were performed: lab tests which revealed elevated transaminases, LDH and CPK and an electromyogram which produced no changes. Clinical judgement diagnosed a non classifiable myopathy, no treatment was administered and medical symptoms spontaneously improved.

In August 2009, medical symptoms worsened, with CPK up to 3000u being detected. She was referred to the rheumatology department where the electromyogram was repeated and

<sup>☆</sup> Please cite this article as: Vargas Lebrón C, Ruiz Montesino MD, Moreira Navarrete V, Toyos Sainz de Miera FJ. Tratamiento con rituximab en dermatomiositis juvenil. Efecto sobre la calcinosis. Reumatol Clin. 2020;16:368–370.



**Fig. 1.** (a) Calcium deposits in peritrochanteric, gluteal and proximal femur regions. (b) Deposits in fascias. (c) Subcutaneous deposits in chest. (d) Disappearance of chest deposits. (e) Evolution of the lesions in lower limbs after treatment.

was compatible with proximal myopathy. Conclusive muscle biopsy confirmed inflammatory myopathy compatible with juvenile dermatomyositis: perivascular inflammatory lymphocytic infiltration.

Treatment was initiated with 30 mg/kg of weight methylprednisolone boluses for 3 consecutive days and oral prednisone and 15–25 mg sc methotrexate per week.

Despite the normalisation of the muscle enzymes, clinical symptoms worsened, proximal muscle strength diminished and cyclosporine was added (up to 4.5 mg/kg).

In November 2010 the joint contractures increased and the patient presented with calcinosis. In January 2011 30 mg IV pamidronate on 3 consecutive days was administered quarterly and 25 mg etanercept per week with no improvement and NMR showed evidence of inflammation in the hip joints. In September 2011 etanercept was suspended and compassionate use of 375 mg/m<sup>2</sup> rituximab in 4 doses was requested. In April 2012 progressive improvement was made with recovery of muscle strength, disappearance of skin lesions and gradual improvement and disappearance of calcinosis (Fig. 1).

In January 2016 immunosuppression was suspended after 2 years in clinical and analytical remission. In January 2018 strength was normal, with no joint contractures or skin lesions and with normal lab test results.

There is no one generally accepted treatment for calcinosis secondary to juvenile dermatomyositis. Different drugs have been used including colchicine, warfarin, intravenous immunoglobulin, thalidomide and calcium channel inhibitors.

Biphosphonates, particularly pamidronate have been shown to be effective in small patient series.<sup>3–7</sup> Rituximab depletes positive CD20 lymphocytes, which are abundant in muscles and peripheral blood in patients with myositis. Few cases in the literature describe the effect on calcinosis.

In our patient the inflammatory activity control, which was not achieved with standard treatment protocols, was the underlying reason for the regression of the calcinosis, in the opinion of her doctors.<sup>8–10</sup> We were unable to determine how much effect the cycles of pamidronate had.

Although we are unable to advocate the use of rituximab in calcinosis of this or other origins (studies are required to demonstrate its use), we have cited this case due to the temporal relationship of the improvement both of the myositis and the calcinosis with the use of rituximab and the depletion of lymphocytes. At present the patient is 15 years old and has been in remission for over 4 years, the first 2 with methotrexate and the last 2 without immunosuppressants.

## Reference

- Rider LG, Lindsley CB, Cassidy JT. Juvenile dermatomyositis. In: James Cassidy JT, Petty RE, Laxer RM, Lindsley CB, editors. *Textbook of pediatric rheumatology*. 6th ed. 2011. p. 375–413.
- Fisler RE, Liang MG, Fuhlbrigge RC, Yalcindag A, Sundel RP. Aggressive management of juvenile dermatomyositis results in improved outcome and decreased incidence of calcinosis. *J Am Acad Dermatol*. 2002;47:505–11.
- Marco Puche A, Calvo Penades I, Lopez Montesinos B. Effectiveness of the treatment with intravenous pamidronate in calcinosis in juvenile dermatomyositis. *Clin Exp Rheumatol*. 2010;28:135–40.
- Hoeltzel MF, Oberle EJ, Robinson AB, Agarwal A, Rider LG. The presentation, assessment, pathogenesis, and treatment of calcinosis in juvenile dermatomyositis. *Curr Rheumatol Rep*. 2014;16:467.

- Martillotti J, Moote D, Zemel L. Improvement of calcinosis using pamidronate in a patient with juvenile dermatomyositis. *Pediatr Radiol*. 2014;44:115–8.
- Slimani S, Abdessemed A, Haddouche A, Ladjouze-Rezig A. Complete resolution of universal calcinosis in a patient with juvenile dermatomyositis using pamidronate. *Joint Bone Spine*. 2010;77:70–2.
- Riley P, McCann LJ, Maillard SM, Woo P, Murray KJ, Pilkington CA. Effectiveness of infliximab in the treatment of refractory juvenile dermatomyositis with calcinosis. *Rheumatology (Oxford)*. 2008;47:877–80.
- Oddis CV, Reed AM, Aggarwal R, Rider LG, Ascherman DP, Levesque MC, et al. Rituximab in the treatment of refractory adult and juvenile dermatomyositis and adult polymyositis: a randomized, placebo-phase trial. *Arthritis Rheum*. 2013;65:314–24.
- Lowry CA, Pilkington CA. Juvenile dermatomyositis: extramuscular manifestations and their management. *Curr Opin Rheumatol*. 2009;21:575–80.
- Alhemairi M, Muzaffer M. Effectiveness of rituximab therapy on severe calcinosis in 4 children with juvenile dermatomyositis. *OJRA*. 2017;7:16–29.

Carmen Vargas Lebrón<sup>a</sup>, María Dolores Ruiz Montesino<sup>b,\*</sup>, Virginia Moreira Navarrete<sup>a</sup>, Francisco Javier Toyos Sainz de Miera<sup>a</sup>

<sup>a</sup> Servicio de Reumatología, Hospital Universitario Virgen Macarena, Sevilla, Spain

<sup>b</sup> Unidad de Imagen, Servicio Reumatología, Hospital Universitario Virgen Macarena, Sevilla, Spain

\* Corresponding author.

E-mail address: [lruizmontesino@yahoo.es](mailto:lruizmontesino@yahoo.es) (M.D. Ruiz Montesino).

<https://doi.org/10.1016/j.reumae.2018.06.003>

2173-5743/© 2018 Elsevier España, S.L.U. and Sociedad Española de Reumatología y Colegio Mexicano de Reumatología. All rights reserved.

### Safety of the administration of local corticosteroids in diabetic patients: Historical cohort study comparing the use of triamcinolone and betamethasone<sup>☆</sup>



#### Seguridad de la administración de corticoides locales en pacientes diabéticos: estudio de cohortes históricas comparando el uso de triamcinolona y betametasona

Dear Editor,

In our specialty the use of local corticosteroids is an extended practice, with the ones most commonly used being triamcinolone-acetonide and betamethasone disodium phosphate.<sup>1</sup> There are many factors which may affect corticosteroids having undesirable systemic effects such as hyperglycaemia.<sup>2</sup> This complication is of particular interest in diabetic patients who are candidates for these medical procedures.

Recently our team conducted a longitudinal historical cohort study to compare the hyperglycaemic effect of intra-synovial corticosteroid infiltrations.

Records of patients with locomotion pains attended between 2014 and 2015 in our hospital were reviewed. During this period our unit had a specific patient register which included a post infiltration follow-up programme which had been partially documented in a previous communication.<sup>3</sup>

The diabetic patient records were analysed where an ultrasound-guided infiltration had been performed and a follow-up file had been completed at least one month after. Only records of intra-articular and intrabursal infiltrations were included.

The available corticosteroids during this period were triamcinolone-acetonide (C<sub>24</sub>H<sub>31</sub>FO<sub>6</sub>, PM = 434.5 g/mol)<sup>4</sup> and betamethasone disodium phosphate (C<sub>22</sub>H<sub>28</sub>FN<sub>2</sub>O<sub>8</sub>P, PM = 516.4 g/mol) + 3 mg of betamethasone-acetonide (C<sub>29</sub>H<sub>33</sub>FO<sub>6</sub>, PM = 496.6 g/mol).<sup>5</sup>

The patients were grouped together depending on the corticosteroid administered. The dependent variables were the number of hyperglycaemias that required emergency medical assessment, changes to their antidiabetic treatment guidelines or the need for hospital admission.

<sup>☆</sup> Please cite this article as: Guillen Astete CA, Diaz Garcia N, Laso Jimeno B, Luque Alarcon M. Seguridad de la administración de corticoides locales en pacientes diabéticos: estudio de cohortes históricas comparando el uso de triamcinolona y betametasona. *Reumatol Clin*. 2020;16:370–371.

Two hundred and fifty eight infiltrations performed on 210 patients were analysed. Of these 210 patients 116 (55.2%) were male. The mean age was 50.3 years, SD: 7.8 (range: 19–92 years). The proportion of patients with a diagnosis of diabetes of over 10 years onset was 61.4%. During the follow-up period 161 infiltrations with betamethasone-acetonide (group A) were performed and 97 with betamethasone disodium phosphate and betamethasone-acetonide (group B). **Table 1** shows the anatomical location of the infiltration distribution.

Simple hyperglycaemia was recorded in 19 patients from group A (11.8%) and 11 patients from group B (11.3%) Simple hyperglycaemias which required emergency medical attention were recorded ( $P > .05$ ). It was not necessary to change oral or insulin antidiabetic guidelines in any case. None of the patients were hospitalized.

Out of the total patients who received an infiltration at shoulder level with any corticosteroid (49), 11 presented with simple hyperglycaemia which required medical assessment. Of these 11 patients, 3 (37.5%) had been immobilised with the use of a sling and 8 had not. Of the 38 patients who did not present with simple hyperglycaemia and who were infiltrated at shoulder level, 34 (89.4%) were immobilised and 4 were not ( $P = .0001$ ; exact Fisher's test). The age of the patients on infiltration administration, the date of diagnosis of diabetes, the type of antidiabetic treatment and the concomitant use of anaesthetics were not associated with

**Table 1**

Distribution of infiltrations according to anatomical location. The magnitudes are expressed in absolute and percentile values with regards to their category.

Location	Group A; N = 161 (%)	Group B; N = 97 (%)
<i>Knee</i>		
External parapatellar recess	46 (28.5)	30 (30.9)
Popliteal bursa	29 (18)	9 (9.2)
Patellar bursa	11 (6.8)	6 (6.1)
<i>Elbow</i>		
Anterior recess	11 (6.8)	7 (7.2)
Olecranon fossa	11 (6.8)	6 (6.1)
Olecranon bursa	9 (5.5)	5 (5.1)
<i>Ankle</i>		
Tibia-talus joint	9 (5.5)	4 (4.1)
<i>Shoulder</i>		
Subacromial deltoid bursa	26 (24.2)	23 (23.7)
Glenohumeral joint	5 (3.1)	4 (4.1)
Carpus	4 (2.4)	3 (3)