

Although IAIC is not a technique that involves important adverse events and does not require long training to be performed in a sufficiently expert way, the authors believe it necessary to prepare guides or recommendations for the technique, for paediatric and young patients (Table 1).

## References

- Nieto-González JC, Monteagudo I. Intra-articular joint injections in juvenile idiopathic arthritis: state of the art. *Reumatol Clin.* 2019;15(2):69–72.
- Jennings H, Hennessy K, Hendry GJ. The clinical effectiveness of intra-articular corticosteroids for arthritis of the lower limb in juvenile idiopathic arthritis: a systematic review. *Pediatr Rheumatol Online J.* 2014;12:23.
- Beukelman T, Guevara JP, Albert DA, Sherry DD, Burnham JM. Usage of intra-articular corticosteroid injections for the treatment of juvenile idiopathic arthritis: a survey of pediatric rheumatologists in the United States and Canada. *Clin Exp Rheumatol.* 2008;26(4):700–3.
- Parra DA. Technical tips to perform safe and effective ultrasound guided steroid joint injections in children. *Pediatr Rheumatol Online J.* 2015;13:2.
- Resnick CM, Vakilian PM, Kaban LB, Peacock ZS. Is intra-articular steroid injection to the temporomandibular joint for juvenile idiopathic arthritis more effective and efficient when performed with image guidance? *J Oral Maxillofac Surg.* 2017;75(4):694–700.
- Peters SE, Laxer RM, Connolly BL, Parra DA. Ultrasound-guided steroid tendon sheath injections in juvenile idiopathic arthritis: a 10-year single-center retrospective study. *Pediatr Rheumatol Online J.* 2017;15(1):22.
- Young CM, Horst DM, Murakami JW, Shiels WE. Ultrasound-guided corticosteroid injection of the subtalar joint for treatment of juvenile idiopathic arthritis. *Pediatr Radiol.* 2015;45(8):1212–7.
- Weiss JE, Haines KA, Chalom EC, Li SC, Walco GA, Nyirenda TL, et al. A randomized study of local anesthesia for pain control during intra-articular corticosteroid injection in children with arthritis. *Pediatr Rheumatol Online J.* 2015;13:36.
- Oren-Ziv A, Hoppenstein D, Shles A, Uziel Y. Sedation methods for intra-articular corticosteroid injections in Juvenile Idiopathic Arthritis: a review. *Pediatr Rheumatol Online J.* 2015;13:28.
- Casado R, Lumbreras J, de Inocencio J, Remesal A, Merino R, García-Consuegra J. Sedation for intra-articular corticosteroid injections in juvenile idiopathic arthritis: the views of patients and their parents. *Eur J Pediatr.* 2013;172(10):1411–3.

Sara Murias Loza,<sup>a,\*</sup> Genaro Graña Gil<sup>b</sup>

<sup>a</sup> Sección de Reumatología Pediátrica, Hospital Universitario La Paz, Madrid, Spain

<sup>b</sup> Servicio de Reumatología, Complejo Hospitalario Universitario A Coruña, A Coruña, La Coruña, Spain

\* Corresponding author.

E-mail address: [saramaria.murias@salud.madrid.org](mailto:saramaria.murias@salud.madrid.org) (S. Murias Loza).

<https://doi.org/10.1016/j.reumae.2019.05.005>

2173-5743/ © 2019 Elsevier España, S.L.U. and Sociedad Española de Reumatología y Colegio Mexicano de Reumatología. All rights reserved.

## Paravertebral pseudotumour in granulomatosis with polyangiitis<sup>☆</sup>



### Seudotumor paravertebral en granulomatosis con poliangeítis

Dear Editor,

Granulomatosis with polyangiitis (GPA) is a type of vasculitis associated with neutrophil anti-cytoplasm antibodies (ANCA) which may affect small and medium calibre vessels.<sup>1</sup> It is characterised by granulomatose lesions and/or necrosing vasculitis in the upper and/or lower respiratory tract, glomerulonephritis and, less often, mucocutaneous, orbital and neurological involvement, among others.<sup>1</sup> Pre- or paravertebral pseudotumour lesions are rare, and there are few reports of them in GPA.<sup>2,3</sup> A case is presented of paravertebral pseudotumour as an incidental finding in the context of systemic GPA involvement.

A 60 year-old man with arterial hypertension and chronic kidney disease that had evolved over 2 years, requiring haemodialysis and previous renal biopsy with sclerosed glomeruli, pericapsular and interstitial fibrosis and atrophic tubules. He visited due to weight loss over 3 months and palpable purpura in the lower limbs. He had symptoms of a compromised upper airway, renal involvement with haematuria and proteinuria in a non-nephrotic range with deterioration of kidney function. Laboratory tests found normocytic normochromic anaemia (haemoglobin 7.1 g/dl and haematocrit 21.9%), normal white blood cells (5,600/mm<sup>3</sup>), accelerated erythrocytation (70 mm/hr.), raised reactive C protein (3.19 mg/dl), creatinine (6.3 mg/dl), proteinuria/creatininuria quotient 2.1 and macroscopic hematuria. ANCA were positive, PR3 ELISA and cytoplasmic pattern in immunofluorescence. The antinuclear antibodies, anti-Ro/SS-A, anti-La/SS-B, anti-DNA and viral serologies for hepatitis B, C and HIV were negative. Computed

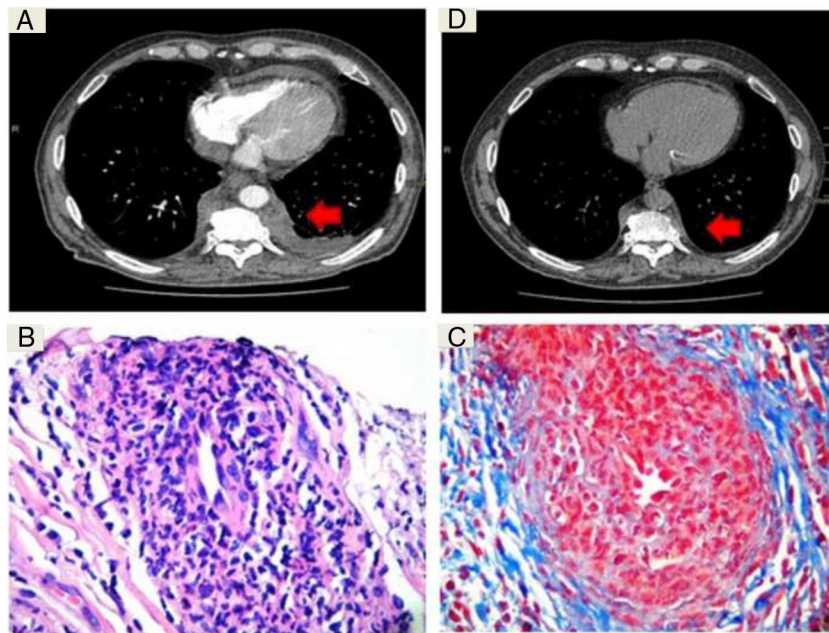
tomography (CT) of the paranasal sinuses showed thickening of the mucosa and bone erosion, and high resolution CT of the thorax revealed centrolobulillar nodules and a paravertebral pseudotumour lesion (Fig. 1A). CT guided biopsy was performed and showed findings that could be associated with vasculitis without granulomatosis (Fig. 1B and C).

Due to the said clinical findings, the positive ANCA and the histological changes in the paravertebral mass, GPA was diagnosed and induction therapy commenced with pulses of methylprednisolone and cyclophosphamide (15 mg/kg/every 15 days/6 doses). Thoracic CT was performed after 4 months, finding a significant reduction in the size of the lesion (Fig. 1D).

Infiltrating pseudotumour lesions are frequent in patients with GPA. They may be located in the orbit, paranasal sinuses, the mediastinum, breast, kidney and retroperitoneum, among other locations.<sup>1</sup> Paravertebral lesions are rare,<sup>2,3</sup> and to our knowledge only 10 cases have been reported in this location, although there are other reports of mediastinal lesions.<sup>2,3</sup> They may present at the moment the disease starts or during its evolution.<sup>2,3</sup> The frequency of such lesions may be underestimated as 50% of cases are asymptomatic and are not associated with bone erosion or the compression of adjacent structures.<sup>2</sup> Some patients may experience chronic thoracic pain.<sup>3</sup> Thoracic CT with contrast and magnetic resonance imaging studies are the main studies suggested for the detection of these lesions and to establish differential diagnoses. Histopathology is essential for diagnosis.<sup>2-4</sup> It also makes it possible to rule out malignancy and other differential diagnoses such as tuberculosis, mycosis, sarcoidosis, histiocytosis and disease associated with IgG4.<sup>4-6</sup> This lesion location gives rise to difficulties in obtaining histological samples, so that it is suggested that a CT-guided biopsy be performed.<sup>2,3</sup> The samples obtained usually show granulomatose infiltrates, rarely vasculitis and calcifications.<sup>2-7</sup> After treatment, the inflammatory lesions may reduce in size, while the lesions that have evolved the most and fibrosis are unchanged.<sup>2-6</sup>

To conclude, GPA should be suspected if there is a finding of paravertebral pseudotumours within an appropriate clinical context.

<sup>☆</sup> Please cite this article as: Flores Balverdi J, Baenas DF, Riscanevo NC, Chiple E, Orozco M, Saurit V. Seudotumor paravertebral en granulomatosis con poliangeítis. *Reumatol Clin.* 2021;17:181–182.



**Fig. 1.** A) Computed tomography with intravenous contrast showing a dorsal paravertebral mass of soft tissues (arrow) which extends to the extrapleural space, without calcifications or bone involvement. B) Fragment of fibroconnective tissue that shows vascular elements with abundant intramural inflammatory infiltrate and reduction in the calibre of openings (H&E  $\times 10$ ). C) Artery with dense mixed inflammatory infiltrate composed of lymphocytes and polymorphonuclear neutrophils, prominent endothelial cells and a narrowed opening (Masson  $\times 40$ ). D) Computed tomography without contrast at check-up, showing a reduction in the lesion after 4 months of treatment.

Obtaining samples for histopathological study is fundamental for the etiological diagnosis.

## References

1. Yates M, Watts R. ANCA-associated vasculitis. *Clin Med (Lond)*. 2017;17:60–4.
2. Barreto P, Pagnoux C, Luca L, Aouizerate J, Ortigueira I, Cohen P, et al. Dorsal prevertebral lesions in Wegener granulomatosis: report on four cases. *Joint Bone Spine*. 2011;78:88–91.
3. Ramirez G, Della-Torre E, Campochiaro C, Bozzolo E, Berti A, Praderio L, et al. Juxta-vertebral lesions in granulomatosis with polyangiitis. *Semin Arthritis Rheum*. 2016;46:356–60.
4. Merkel PA, McCarty D, Sharma A, Stone JR. Case records of the Massachusetts General Hospital. Case 31-2008. A 39-year-old man with chest pain, arthralgias, and a mediastinal mass. *N Engl J Med*. 2008;359:1603–14.
5. Anderson G, Coles ET, Crane M, Douglas AC, Gibbs AR, Geddes DM, et al. Wegener's granuloma: a series of 265 British cases seen between 1975 and 1985: a report by a sub-committee of the British Thoracic Society Research Committee. *Q J Med*. 1992;83:427–38.
6. Fidler HH, Apter S, Langevitz P, AvielRonen S, Bank I, Livneh A, et al. Positive antineutrophil cytoplasmic antibodies-associated vasculitis presenting with hemoptysis and a mediastinal mass. *Chest*. 1999;115:1473–5.

7. George TM, Cash JM, Farver C, Sneller M, van Dyke CW, Derus CL, et al. Mediastinal mass and hilar adenopathy: rare thoracic manifestations of Wegener's granulomatosis. *Arthritis Rheum*. 1997;40:1992–7.

Janet Flores Balverdi,<sup>a</sup> Diego Federico Baenas,<sup>a,\*</sup> Nadia Claudine Riscanevo,<sup>a</sup> Emilia Chiple,<sup>b</sup> Maira Orozco,<sup>c</sup> Verónica Saurit<sup>a</sup>

<sup>a</sup> Servicio de Reumatología, Hospital Privado Universitario de Córdoba, Córdoba, Argentina

<sup>b</sup> Servicio de Anatomía Patológica, Hospital Privado Universitario de Córdoba, Córdoba, Argentina

<sup>c</sup> Servicio de Diagnóstico por Imágenes, Hospital Privado Universitario de Córdoba, Córdoba, Argentina

\* Corresponding author.

E-mail address: [diegob.17@hotmail.com](mailto:diegob.17@hotmail.com) (D.F. Baenas).

<https://doi.org/10.1016/j.reumae.2020.02.001>

2173-5743/ © 2019 Elsevier España, S.L.U. and Sociedad Española de Reumatología y Colegio Mexicano de Reumatología. All rights reserved.