



Sociedad Española
de Reumatología -
Colegio Mexicano
de Reumatología

Reumatología Clínica

www.reumatologiaclinica.org



Images in Clinical Rheumatology

Hip pain secondary to intermuscular lipoma[☆]

Dolor de cadera secundario a lipoma intermuscular

Francisco Vílchez-Oya,^{*} Tarek Carlos Salman-Monte, Jordi Monfort

Servicio de Reumatología, Parc de Salut Mar/Hospital del Mar, Barcelona, Spain



ARTICLE INFO

Article history:

Received 17 March 2019

Accepted 3 July 2019

Available online 6 March 2020

An 83-year-old male with a 2-history of right hip pain. Initial examination showed moderate pain on palpation of the right trochanteric region with no phlogistic signs and no limitation of joint range. With an initial diagnosis of trochanteric bursitis, treatment with oral anti-inflammatories was initiated. Due to persistent pain, glucocorticoid injection was given. However, the symptoms persisted, and functional limitation was evident months following onset.

Reassessment showed pain on palpation of moderate-severe intensity together with a hard, non-stony tumor with flogotic signs seated on the upper third of the lateral face of the affected limb. An MRI of both hips was requested (Fig. 1), which showed edema in the soft tissues around the right greater trochanter, compatible with enthesitis, as well as a well-defined ovoid lesion,

42 mm×38 mm×77 mm, located in the deep plane between the belly of the tensor muscle of the fascia lata and the sartorius muscle. Biopsy showed multiple foci of steatonecrosis with associated xanthomatous reaction. The lesion was surgically removed, with good clinical outcome.

The latent clinical course and slow growth of the tumor could discourage the physician from suspecting a pathology with potential risk.^{1–4} However, persistent unilateral pain, in the absence of other factors, should alert suspicion of an unusual pathology.^{5–7} In this regard, the frequency of intramuscular lipomas is approximately 0%–5%, and .3%–1.9% for intermuscular lipomas, the most common location being the thigh.^{8–10} Our case highlights the importance of confirming the nature of any soft tissue inflammatory process with additional imaging tests and biopsy, if necessary.

[☆] Please cite this article as: Vílchez-Oya F, Salman-Monte TC, Monfort J. Dolor de cadera secundario a lipoma intermuscular. Reumatol Clin. 2021;17:175–177.

^{*} Corresponding author.

E-mail address: fvilchez@outlook.es (F. Vílchez-Oya).

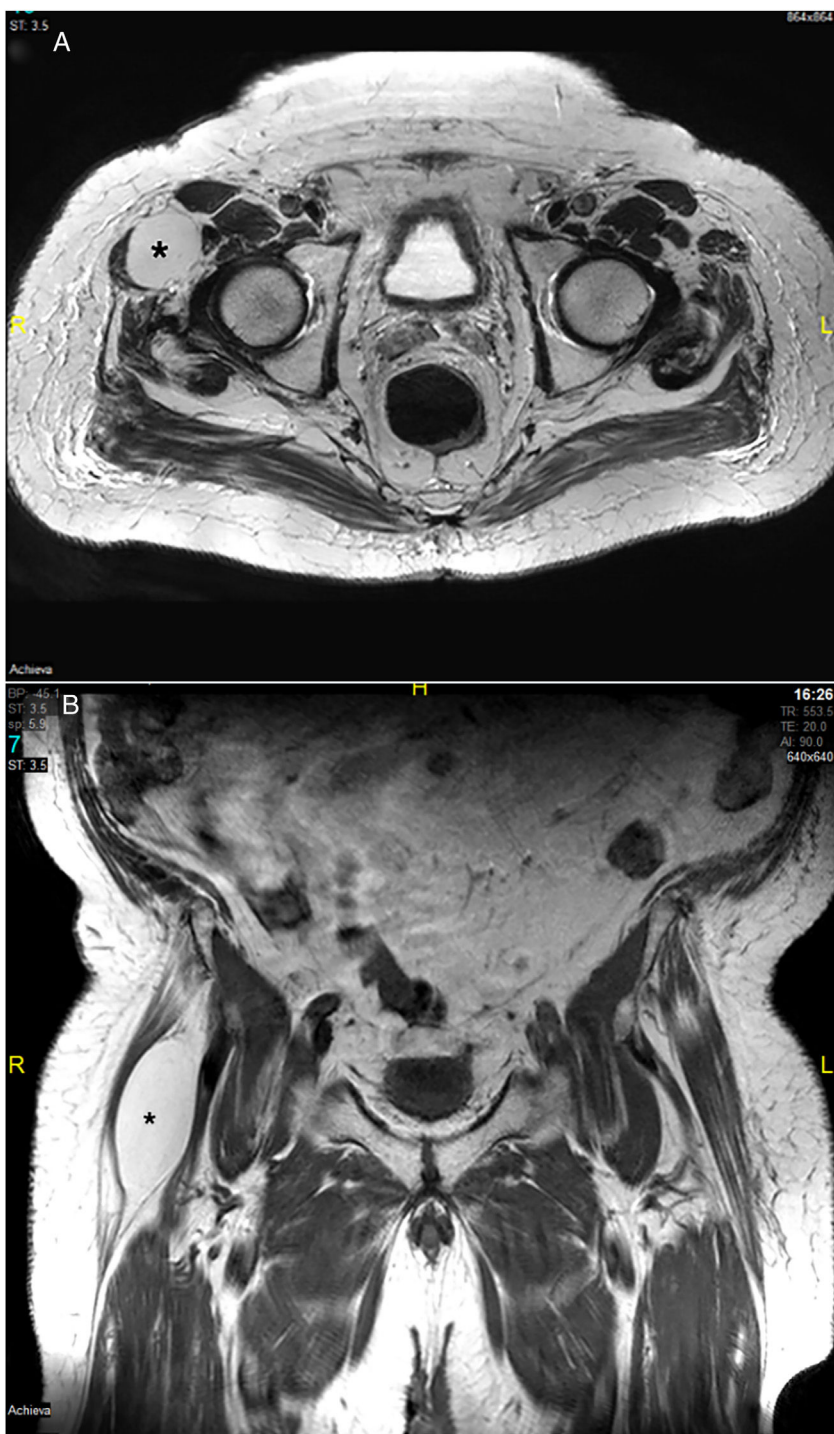


Fig. 1. Ovoid lesion (*) between the belly of the fascia lata tensor muscle and the sartorius muscle. (A) Hip MRI, axial plane. (B) Hip MRI, coronal plane.

Funding

The authors declare that they have received no funding for this paper.

Conflict of interests

The authors have no conflict of interests to declare.

References

1. Weiss SW, Goldblum JR. Benign lipomatous tumors. In: Enzinger and Weiss's Soft Tissue Tumors. 4th edition St. Louis: Mosby; 2001. p. 571–639.
2. Nielsen GP, Mandahl N. Lipoma. In: Fletcher CD, Unni KK, Mertens F, editors. Pathology and genetics of tumours of soft tissue and bone. Lyon: IARC Press; 2002. p. 20–2.
3. Weiss SW, Goldblum JR. Liposarcoma. In: Enzinger and Weiss's soft tissue tumors. 4th edition St. Louis: Mosby; 2001. p. 641–93.
4. Fletcher CD, Martin-Bates E. Intramuscular and intermuscular lipoma: neglected diagnoses. *Histopathology*. 1988;12:275–87.

5. Dalal KM, Antonescu CR, Singer S. Diagnosis and management of lipomatous tumors. *J Surg Oncol.* 2008;97:298–313.
6. Zhang H, Erickson-Johnson M, Wang X, Oliveira JL, Nascimento AG, Sim F-H, et al. Molecular testing for lipomatous tumors: critical analysis and test recommendations based on the analysis of 405 extremity-based tumors. *Am J Surg Pathol.* 2010;34:1304–11.
7. Kooby DA, Antonescu CR, Brennan MF, Singer S. Atypical lipomatous tumor/well-differentiated liposarcoma of the extremity and trunk wall: importance of histological subtype with treatment recommendations. *Ann Surg Oncol.* 2004;11:78–84.
8. Dei Tos AP, Pedeutour F. Atypical lipomatous tumor. In: Fletcher CDM, Bridge JA, Hogendoorn PCW, Mertens F, editors. WHO classification of tumors of soft tissue and bone. 4th edition Lyon: IARC Press; 2013. p. 33–6.
9. Warner JJ, Madsen N, Gerber C. Intramuscular lipoma of the deltoid causing shoulder pain: report of two cases. *Clin Orthop.* 1990;253:110–2.
10. Evans HL, Soule EH, Winkelmann RK. Atypical lipoma, atypical intramuscular lipoma, and well-differentiated retroperitoneal liposarcoma: a reappraisal of 30 cases formerly classified as well-differentiated liposarcoma. *Cancer.* 1979;43:574–84.