




Sociedad Española
de Reumatología -
Colegio Mexicano
de Reumatología

Reumatología Clínica

www.reumatologiaclinica.org



Case Report

X-linked hypophosphatemic rickets: Diagnosis in adult and paucisymptomatic form[☆]

Luis Carlos López-Romero,^{a,*} Jose Jesús Broseta,^b Elena Guillén Olmos,^b
Ramón Jesús Devesa-Such,^a Julio Hernández-Jaras^a

^a Servicio de Nefrología, Área Clínica del Riñón y Vías Urinarias, Hospital Universitari i Politècnic La Fe, Valencia, Spain

^b Servei de Nefrologia i Trasplantament Renal, Institut Clínic de Nefrologia i Urologia, Hospital Clínic de Barcelona, Barcelona, Spain



ARTICLE INFO

Article history:

Received 7 June 2019

Accepted 31 July 2019

Available online 3 March 2020

Keywords:

X-linked hypophosphatemic rickets
Osteomalacia
Burosumab

ABSTRACT

X-linked hypophosphatemic rickets (XLH) is the main form of hereditary rickets caused by mutation of the PHEX gene and occurs mainly in childhood. Clinically, it causes growth retardation and bone deformities; however, there are atypical forms of presentation that make diagnosis difficult. We present a case of XLH of late diagnosis and paucisymptomatic form with multiple fractures and greatly affecting quality of life, under treatment with traditional therapy for this disease.

© 2019 Elsevier España, S.L.U. and Sociedad Española de Reumatología y Colegio Mexicano de Reumatología. All rights reserved.

Raquitismo hipofosfatémico ligado al cromosoma X: diagnóstico en la edad adulta y forma paucisintomática

RESUMEN

El raquitismo hipofosfatémico ligado al cromosoma X (XLH) es la principal forma de raquitismo hereditario causada por la mutación del gen PHEX y que se manifiesta principalmente en la infancia. Clínicamente cursa con retraso en el crecimiento y deformidades óseas, sin embargo, existen formas de presentación atípicas que dificultan el diagnóstico. Presentamos un caso de XLH con diagnóstico tardío y forma paucisintomática que presenta múltiples fracturas y gran afectación en su calidad de vida, en tratamiento con la terapia clásica para esta enfermedad.

© 2019 Elsevier España, S.L.U. y Sociedad Española de Reumatología y Colegio Mexicano de Reumatología. Todos los derechos reservados.

Palabras clave:

Raquitismo hipofosfatémico ligado al cromosoma X
Osteomalacia
Burosumab

Introduction

X-linked hypophosphatemic rickets (XLH) is a hereditary disease caused by mutation of the PHEX gene located on locus Xp22.11.¹ This gene codes for phosphate-regulating endopeptidase whose function is to inhibit fibroblast growth factor 23 (FGF-23). Increased FGF-23 decreases tubular phosphate resorp-

tion (TPR) and Alpha-1-hydroxylase activity, resulting in reduced serum levels of 1.25-dihydroxyvitamin D, hypophosphaturia and hypophosphatemia.²

The main clinical findings include rickets, osteomalacia, growth retardation, bone pain and enthesopathies. However, there are paucisymptomatic forms that only manifest with chronic pain, osteoarthritis and muscle weakness, this hinders and delays diagnosis, requiring multidisciplinary management.³ Treatment is based on phosphorus and calcitriol supplements; however, the appearance of the human monoclonal anti-FGF23 antibody enables the disease mechanism to be blocked and its natural history modified.

[☆] Please cite this article as: López-Romero LC, Broseta JJ, Olmos EG, Devesa-Such RJ, Hernández-Jaras J. Raquitismo hipofosfatémico ligado al cromosoma X: diagnóstico en la edad adulta y forma paucisintomática. Reumatol Clin. 2021;17:116–117.

* Corresponding author.

E-mail address: luiscarlosopezromero@gmail.com (L.C. López-Romero).

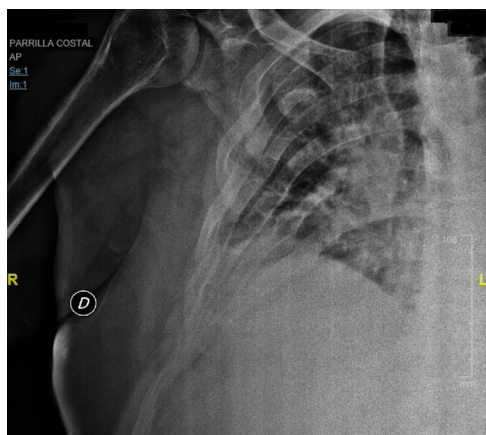


Fig. 1. Right scapula fracture. Multiple fracture calluses in right costal area.

Clinical case

A 35-year-old male with a history of chronic disabling low back pain and myalgias of several years' duration, without signs of osteoarthritis or constitutional symptoms, referred for assessment by rheumatology. Physical examination was normal, height 185 cm and BP 145/85 mmHg. Of note in the complementary tests: phosphorus 1.7 mg/dl (normal range [NR]: 2.7–4.5 mg/dl), parathyroid hormone 85.2 pg/ml (NR: 15–65 pg/ml), 1,25 dihydroxyvitamin D 18.7 ng/ml (NR: ≥ 30 ng/ml), creatinine .9 mg/dl (NR: .5–.95 mg/dl), alkaline phosphatase 167 I/U (NR: 35–105 I/U), phosphaturia 2.088 mg/24 h with TRP of 55% (NR: $\geq 80\%$). The rest of the results were normal.

He presented multiple fractures in the ribs and right scapula due to an accidental fall (Fig. 1) and densitometry with signs of osteopenia in the spine. In view of these findings, treatment with phosphate, calcitriol and analgesics was started.

Tumour osteomalacia was ruled out as a possible cause, and therefore a genetic study was carried out which confirmed the diagnosis of XLH with mutation in the PHEX gene (4c.1645t). Treatment with phosphorus and calcitriol is currently being maintained, but the low back pain persists greatly affecting the patient's quality of life. Therefore, this patient would be a good candidate for burosumab.

Discussion

Diagnosing rare diseases is a challenge, especially XLH, whose phenotypic expression is very variable. Although most cases are

diagnosed during childhood, this case is an example of a form of presentation that is not very expressive and has a wide differential diagnosis that could require the participation of various specialists.

Genetic tests help in the cases with atypical presentations or in adulthood where tumoral osteomalacia is the main possibility. Classical treatment with phosphate and calcitriol leads to side effects that limit adherence to treatment in the long term, but treatment with burosumab has shown very positive results in children as well as adults.^{4,5} It has been related to clinical improvement, correction of deformities, normalisation of growth and phosphorus levels in a sustained manner, with good results also in patients who, although they have completed their growth, continue with significant limitations to their quality of life due to the sequelae of the disease.^{6,7}

In conclusion, we must be alert to these cases of XLH of difficult diagnosis due to their paucisymptomatic presentation that can be referred to us without a diagnosis in adulthood. Burosumab could be very useful in the treatment of adult patients with significant limitations to their quality of life.

Conflict of interests

The authors have no conflict of interests to declare.

References

1. Whyte MP, Schranck FW, Armamento-Villareal R. X-linked hypophosphatemia: a search for gender, race, anticipation, or parent of origin effects on disease expression in children. *J Clin Endocrinol Metab.* 1996;81:4075–80.
2. Yuan B, Takaiwa M, Clemens TL, Feng JQ, Kumar R, Rowe PS, et al. Aberrant PheX function in osteoblasts and osteocytes alone underlies murine X-linked hypophosphatemia. *J Clin Invest.* 2008;118:722–34.
3. Friedman NE, Lobaugh B, Drezner MK. Effects of calcitriol and phosphorus therapy on the growth of patients with X-linked hypophosphatemia. *J Clin Endocrinol Metab.* 1993;76:839–44.
4. Lamb YN. Burosumab: first global approval. *Drugs.* 2018;78:707–14.
5. FDA News Release: FDA approves first therapy for rare inherited form of rickets, X-linked hypophosphatemia. Available from: <https://www.fda.gov/NewsEvents/Newsroom/PressAnnouncements/ucm604810.htm> [accessed 25.05.18].
6. Imel EA, Glorieux FH, Whyte MP, Munns CF, Ward LM, Nilsson O, et al. Burosumab versus conventional therapy in children with X-linked hypophosphatemia: a randomised, active-controlled, open-label, phase 3 trial. *Lancet.* 2019;293:2416–27.
7. Portale AA, Carpenter TO, Brandi ML, Briot K, Cheong HI, Cohen-Solal M, et al. Continued beneficial effects of burosumab in adults with X-linked hypophosphatemia: results from a 24-week treatment continuation period after a 24-week double-blind placebo-controlled period. *Calcif Tissue Int.* 2019;105:271–84. <http://dx.doi.org/10.1007/s00223-019-8-3-0056>.