



Sociedad Española  
de Reumatología -  
Colegio Mexicano  
de Reumatología

# Reumatología Clínica

www.reumatologiaclinica.org



## Case Report

### Uncommon causes of nerve compression in the distal forearm

Soraia Azevedo<sup>a,\*</sup>, Francisca Guimarães<sup>a</sup>, Joana Ramos Rodrigues<sup>a</sup>, Ricardo Branco<sup>b</sup>,  
Elisa Rodrigues<sup>b</sup>, Filipa Teixeira<sup>a</sup>

<sup>a</sup> Rheumatology Department, Unidade Local de Saúde do Alto Minho, Ponte de Lima, Portugal

<sup>b</sup> Orthopedic Department, Unidade Local de Saúde do Alto Minho, Viana do Castelo, Portugal

#### ARTICLE INFO

##### Article history:

Received 18 April 2020

Accepted 10 June 2020

##### Keywords:

Median nerve compression

Carpal tunnel

Abnormal mass

Lipoma

Accessory muscle

#### ABSTRACT

**Introduction:** Nerve compression by anomalous masses located at the wrist and distal forearm is an infrequent condition. They may compress underlying structures in the carpal tunnel region, causing pain and paresthesias, which leads to the wrong diagnosis of carpal tunnel syndrome.

**Clinical cases:** We present three cases of patients with symptomatology and clinical tests compatible with compression of the median nerve in the carpal tunnel but whose physical examination showed a soft mass in the distal region of the forearm which was compressing the median nerve, as demonstrated by ultrasound evaluation.

**Discussion:** The reported cases of accessory muscles or lipomas described in the literature as causes of median nerve compression clinic are mainly described only after the surgical decompression of the carpal tunnel, due to the maintenance of residual symptoms.

**Conclusion:** Careful examination with an ultrasound evaluation prior to surgery may help to identify these cases and help planning surgical treatment.

© 2020 Elsevier España, S.L.U. and Sociedad Española de Reumatología y Colegio Mexicano de Reumatología. All rights reserved.

### Causas poco frecuentes de compresión nerviosa en el antebrazo distal

#### RESUMEN

**Introducción:** La compresión del nervio mediano por masas anómalas localizadas en la muñeca y en el antebrazo distal es una condición infrecuente. Las estructuras subyacentes en la región del túnel carpiano pueden ser comprimidas, causando dolor y parestesias, pudiendo llevar al diagnóstico erróneo de síndrome del túnel carpiano.

**Casos clínicos:** Se presentan 3 casos de pacientes con symptomatología y pruebas clínicas compatibles con compresión del nervio mediano en el túnel carpiano. Sin embargo, a la inspección presentaban leve edema en la región proximal del canal, y en la evaluación por ultrasonido se detectó sendas tumoraciones que comprimían el nervio mediano previo a su ingreso en el canal carpiano.

**Discusión:** En la literatura, los casos de músculos accesorios o lipomas como causas de compresión del nervio mediano son las causas más probables de persistencia de los síntomas tras la descompresión quirúrgica del canal carpiano.

**Conclusión:** La exploración clínica detallada junto con la evaluación ultrasonográfica antes de la cirugía pueden ayudar a identificar estos casos y planificar un mejor abordaje quirúrgico.

© 2020 Elsevier España, S.L.U. y Sociedad Española de Reumatología y Colegio Mexicano de Reumatología. Todos los derechos reservados.

##### Palabras clave:

Compresión del nervio mediano

Túnel carpiano

Masa anormal

Lipoma

Músculo accesorio

#### Introduction

Symptomatic compression neuropathy of the median nerve is a frequent entity.<sup>1</sup> The most common cause of the median nerve

\* Corresponding author.  
E-mail address: soraia.azevedo@ulsam.min-saude.pt (S. Azevedo).

compression is carpal tunnel syndrome (CTS) due to thickening of the anterior annular ligament.<sup>2</sup> Nerve compression by anomalous masses located at the wrist and distal forearm is an infrequent condition.<sup>3</sup>

Accessory muscles and other masses, like lipomas, may compress underlying structures in the carpal tunnel region, causing pain and paresthesias, leading to the diagnosis of CTS, which can mislead to a wrong diagnosis of thickening of the anterior annular ligament.

### Clinical cases

We present three cases of patients with symptoms and clinical tests (Tinel's and Phalen's) compatible with compression of the median nerve in the carpal tunnel who showed, on clinical examination, a soft tissue mass in the distal region of the forearm. The ultrasound (US) evaluation revealed a mass, of different aetiologies, compressing the median nerve.

#### Clinical case 1

A 31-year-old woman, whose electromyogram revealed a sensory latency of the left median nerve in the wrist, compatible with mild CTS, presented a soft tissue mass that, on US, corresponded to an accessory muscle. A wrist MRI showed a "muscle mass, which may correspond to an anatomical variant at this level and the median nerve shows a hypersignal proximal to the carpal tunnel." A surgical exploration of the carpal tunnel was performed, allowing the identification and release of the median nerve and the excision of an exuberant muscular mass that corresponded to an accessory *flexor digitorum superficialis indicis*. After two months of follow-up, the patient referred total resolution of the complaints of paresthesia and neuropathic pain (Fig. 1A–D).

#### Clinical case 2

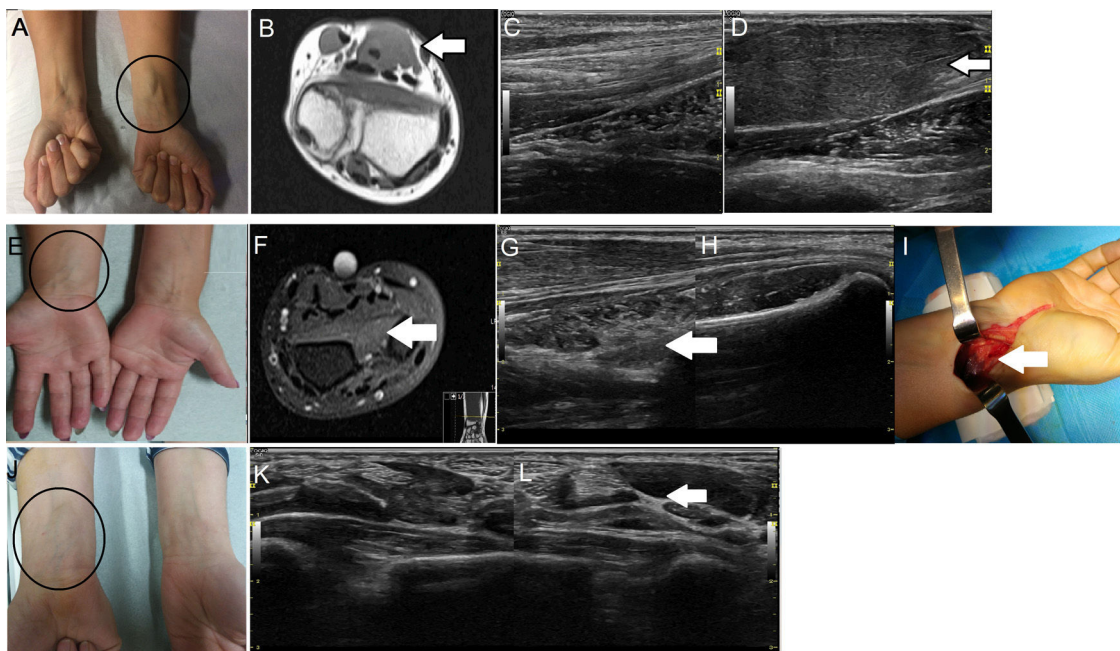
A 43-year-old woman, with an unremarkable electromyogram, was submitted to an US evaluation of the wrist, which revealed that the mass on the dorsal flexor surface corresponded to a hyperechoic mass compared to the surrounding hypoechoic fat, with fibrous capsule and no posterior acoustic enhancement. The MRI revealed "muscular groups of the volar surface of the distal forearm with mild hypersignal of the *pronator quadratus*, which may be due to overuse or translate innervation interfere". The surgical exploration revealed a lipoma which was surgically extracted (Fig. 1E–I).

#### Clinical case 3

A 45-year-old woman, with a normal electromyogram, whose soft tissue mass on the forearm corresponded, on US evaluation, to a muscle mass that was compressing the median nerve. The patient is currently waiting for surgical releasing of the median nerve (Fig. 1J–L).

### Discussion

CTS is one of the most common peripheral neuropathies in the upper extremity. It is defined as an entrapment syndrome of the median nerve at the level of the distal forearm.<sup>2</sup> Median nerve compression at the wrist can also result from accessory flexor tendons or hypertrophic muscles. Although rare, these anatomic variances need to be considered, especially in the presence of a mass in the distal region of the forearm, such as in the reported cases. Lipomas are the most frequent human tumors and are generally asymptomatic. However, as in the clinical case 2, they can compress some structures, including nerves.<sup>4</sup> In literature, the reported cases of accessory muscles and other masses causing median nerve compression are mainly described in patients with residual symptoms after the surgical decompression of the carpal tunnel.<sup>4,5</sup>



**Fig. 1. Clinical case 1. A:** Swelling of the forearm (circle); **B:** Magnetic resonance imaging showing a muscle mass, which may correspond to the anatomical variant (arrow); **C:** Ultrasound of normal forearm; **D:** Ultrasound of accessory flexor digitorum superficialis indicis muscle (arrow). **Clinical case 2. E:** Swelling of the forearm (circle); **F:** Magnetic resonance imaging showing mild hypersignal of the pronator quadratus (arrow); **G:** Ultrasound showing a hypoechoic mass (arrow); **H:** Ultrasound of normal forearm; **I:** Surgical exploration that revealed a lipoma. **Clinical case 3. J:** Swelling of the forearm (circle); **K:** Ultrasound of normal forearm; **L:** Ultrasound of a hypoechoic mass that compressed the median nerve, suggestive of lipoma or muscle mass (arrow).

## Conclusion

US evaluation prior to the median nerve decompression surgery is of utmost importance since it allows an adequate differential diagnosis, helping identifying these cases and planning surgical approach.

## Authors' statement

Authors declare that the manuscript has not been submitted or published elsewhere with the exception of abstracts published with scientific meetings

## Compliance with ethical standards

These patients gave your informed consent in accordance with the 1964 Helsinki declaration.

## Conflict of interests

The authors declare they have no conflicts of interest.

## References

1. Graham B, Peljovich AE, Afra R, Cho MS, Gray R, Stephenson J, et al. The American Academy of Orthopaedic Surgeons evidence-based clinical practice guideline on: management of carpal tunnel syndrome. *J Bone Joint Surg Am.* 2016;98:1750–4, <http://dx.doi.org/10.2106/JBJS.16.00719>.
2. LeBlanc KE, Cestia W. Carpal tunnel syndrome. *Am Fam Physician.* 2011;83:952–8.
3. Dang AC, Rodner CM. Unusual compression neuropathies of the forearm, part II: median nerve. *J Hand Surg Am.* 2009;34:1906–14, <http://dx.doi.org/10.1016/j.jhsa.2009.10.016>.
4. Valbuena SE, O'Toole GA, Roulot E. Compression of the median nerve in the proximal forearm by a giant lipoma: a case report. *J Brachial Plex Peripher Nerve Inter.* 2008;3:17, <http://dx.doi.org/10.1186/1749-7221-3-17>.
5. Vanhoenacker FM, Desimpel J, Mespreuve M, Tagliafico A. Accessory muscles of the extremities. *Semin Musculoskelet Radiol.* 2018;22:275–85, <http://dx.doi.org/10.1055/s-0038-1641575>.