




Sociedad Española  
de Reumatología -  
Colegio Mexicano  
de Reumatología

# Reumatología Clínica

www.reumatologiaclinica.org



## Case Report

### Diffuse idiopathic skeletal hyperostosis in a young woman treated with isotretinoin



Monica Ibáñez Barceló<sup>a,\*</sup>, Ana Estremera Rodrigo<sup>b</sup>, Inmaculada Ros Vilamajó<sup>a</sup>, Antonio Juan Mas<sup>a</sup>

<sup>a</sup> Department of Rheumatology, Hospital Son Llàtzer, Palma de Mallorca, Spain

<sup>b</sup> Department of Radiology, Hospital Son Llàtzer, Palma de Mallorca, Spain

#### ARTICLE INFO

##### Article history:

Received 26 April 2020

Accepted 10 September 2020

##### Keywords:

Diffuse idiopathic skeletal hyperostosis  
Isotretinoin

##### Palabras clave:

Hiperostosis anquilosante vertebral difusa  
Isotretinoína

#### ABSTRACT

We present the case of a 36-year-old woman with diffuse idiopathic skeletal hyperostosis especially at cervical spine since she was 29 years old. The only relevant feature was the use of isotretinoin at regular doses in the past for severe acne.

© 2020 Elsevier España, S.L.U. and Sociedad Española de Reumatología y Colegio Mexicano de Reumatología. All rights reserved.

### Hiperostosis anquilosante vertebral difusa en una mujer joven tratada con isotretinoína

#### RESUMEN

Se presenta el caso de una paciente de 36 años con hiperostosis anquilosante vertebral difusa de predominio cervical desde los 29 años. El único antecedente a destacar es el uso de isotretinoína a dosis adecuadas para el tratamiento de acné severo.

© 2020 Elsevier España, S.L.U. y Sociedad Española de Reumatología y Colegio Mexicano de Reumatología. Todos los derechos reservados.

## Introduction

The use of isotretinoin is common for the treatment of acne. Patients are used to give their informed and written consent before treatment for the risk of teratogenicity. However, many of them are not aware of the possible skeletal side effects at long term.

Skeletal hyperostosis is rare in young patients. As rheumatologists, in patients with diffuse idiopathic skeletal hyperostosis we are used to ask well-known comorbidities such as obesity, high blood pressure, diabetes mellitus, hyperinsulinemia, dyslipidemia, and hiperuricemia.<sup>1</sup> However, the use of isotretinoine and the cumulative doses is not always being considered.

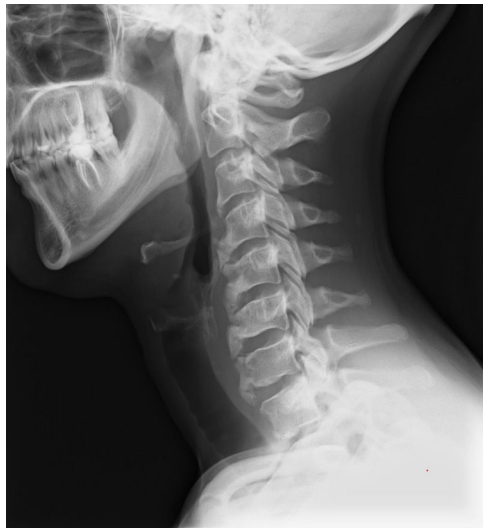## Case report

We describe a 36 year-old woman with intermittent periods of pain and stiffness in her cervical spine since she was 29. Her past medical history was unremarkable except for the use of isotretinoin for severe acne since she was 25 years old. She received 2 previous courses of isotretinoin in another center with no information about the cumulative dose. However, the patient reassures that she only completed the treatment in the first course. In the second and in the third one, as the acne resolved quickly, as soon as she improved, she stopped the medication on her own. She came to our hospital for the third course. She received 20mg of oral isotretinoin daily, however she presented side effects almost immediately (nausea). Therefore, the dosis was lowered to 10mg daily. The cumulative dose of isotretinoin in the third course was 4765 mg.

She referred intermittent chronic cervical pain and morning stiffness of 10 min. She did not refer pain at night, or at other sites: no pain at dorso-lumbar spine, sacroiliac joints, peripheral joints or

\* Corresponding author.

E-mail address: [mibanez@hsl.es](mailto:mibanez@hsl.es) (M. Ibáñez Barceló).



**Fig. 1.** lateral cervical spine X-RAY shows ossification along the anterior aspect of the vertebral bodies from C3 to C7, preservation of disc height in the involved levels and the absence of bony ankylosis of facet joints.

enthesal symptoms. No psoriasis, uveitis or inflammatory bowel disease in her past medical history. She was healthy and fit doing regular pilates and running. She worked as a waitress. She used ibuprofen 600 mg every eight hours and diazepam 5 mg at flares.

On physical examination, her weight was 50 kg. She had cervical tenderness and contracture of trapezius muscles with limited rotations (60°) at cervical spine. No pain at sacroiliac joints, peripheral joint or enthesal sites. The neurological exploration, as well as the rest of the physical examination, was normal.

Laboratory findings were unremarkable: erythrocyte sedimentation rate (ESR): 11 mm/h; C-reactive protein (CRP): 0.8 mg/L (reference range 0–5), human leucocyte antigen-B27 was negative; glucose, lipidic screen and uric acid were within the normal range as well as calcium, phosphate, alkaline phosphatase, vitamin D, vitamin A, calcium, urinary calcium, thyroid and parathyroid hormone.

She had an X-ray of her cervical spine (Fig. 1). Interestingly, radiological progression was also observed in asymptomatic locations, such as dorsal spine, pelvis with mild enthesopathy at the iliac crests and right trochanter and hindfoot with signs of enthesitis at both achilles tendon insertions. The echocardiogram ruled out cardiac valve calcification.

She received ibuprofen at regular doses, physiotherapy and dry needling with mild improvement of her symptoms.

## Discussion

Skeletal hyperostosis is rare in young patients. According to the literature, the development of isotretinoin-induced skeletal hyperostosis appears 3–5 years after the treatment, with cervical spine and feet being the most frequent affected areas.

Although this side effect has been described by many authors since 1983,<sup>2–9</sup> we observe that many patients are not aware of this complication. Although our report is a single case, correlates with literature.

This case report has several limitations. First of all, we can't give precise information about the total dosis of isotretinoin. Although the maximum cumulative dose of isotretinoin ranges from 120–150mg /kg (safety data sheet according), relapses of severe acne vulgaris are very common, and for decreasing relapse rates is common to receive higher doses of isotretinoin.<sup>10</sup> Our message is that this side effect can occur in daily clinical practice.

Secondly, we don't have a basal cervical x- ray to compare because she didn't have cervical pain at that time. She began with cervical pain at 29 years old without any previous injury.

We wonder if the cumulative dose should be reduced or the patient should receive more concise information about long term complications.

## Conclusions

In young patients with diffuse idiopathic skeletal hiperostosis, beside the cardiovascular comorbidities, we should consider the use of isotretinoin and the cumulative doses.

**Informed consent** was obtained from the patient for the publication of this report.

## Conflict of interests

The authors declare that they have no conflict of interest.

## References

- Mader R, Novofestovski I, Adawi M, Lavi I. Metabolic syndrome and cardiovascular risk in patients with diffuse idiopathic skeletal hiperostosis. *Semin Arthritis Rheum.* 2009;38:361–5.
- Pittsley RA, Yoder FW. Retinoid hyperostosis Skeletal toxicity associated with long-term administration of 13-cis-retinoic acid for refractory ichthyosis. *N Engl J Med.* 1983;308:1012–4.
- Montag M, Reiser M, Hamm H, Traupe H, Vogt HJ. Skelettveränderungen nach Langzeitbehandlung mit Retinoiden [Skeletal changes following long-term treatment with retinoids]. *Radiologe.* 1988;28:320–5.
- Zhao S, Goodson NJ. Diffuse idiopathic skeletal hyperostosis and isotretinoin in cystic acne. *BMJ Case Rep.* 2015;2015, pii: bcr2015209775.
- Ling TC, Parkin G, Islam J, Seukeran DC, Cunliffe WJ. What is the cumulative effect of long-term, low-dose isotretinoin on the development of DISH? *Br J Dermatol.* 2001;144:630–2.
- Scott WG, Samuel LW. Isotretinoin-induced skeletal hyperostosis, vol. 3. SpringerPlus; 2014. p. 698.
- Kilcoyne RF, Cope R, Cunningham W, Nardella FA, Denman S, Franz TJ, et al. Minimal spinal hyperostosis with low-dose isotretinoin therapy. *Invest Radiol.* 1986;21:41–4.
- Pennes DR, Martel W, Ellis CN, Voorhees JJ. Evolution of skeletal hyperostoses caused by 13-cis-retinoic acid therapy. *Am J Roentgenol.* 1988;151:967–73.
- Tangrea JA, Kilcoyne RF, Taylor PR, Helsel WE, Adrianza ME, Hartman AM, et al. Skeletal hyperostosis in patients receiving chronic, very-low-dose isotretinoin. *Arch Dermatol.* 1992;128:921–5.
- Blasiak RC, Stamey CR, Burkhart CN, Lugo-Somolinos A, Morrell DS. Highdose isotretinoin treatment and the rate of retreatment, relapse, and adverse effects in patients with acne vulgaris. *Jama Dermatol.* 2013;149:1392–8.