



Case Report

Adjuvant Induced Autoimmune/Inflammatory Syndrome Presenting as Joint and Lung Manifestations[☆]



Guillermo Flores Padilla, Benjamín Mora Mendoza, Axel Pedraza Montenegro*

Servicio de Medicina Interna, Hospital de Especialidades, Centro Médico Nacional Siglo XXI, IMSS, Mexico City, Mexico

ARTICLE INFO

Article history:

Received 4 March 2013

Accepted 24 January 2014

Available online 9 May 2014

Keywords:

Autoimmune

Adjuvants

Granulomatosis

ABSTRACT

A 59-year-old female with a history of injection of an oily material in the buttocks 11 years ago. She developed symmetric additive polyarthritis as well as superior and inferior airways involvement. There was no evidence of granulomatosis with polyangiitis (Wegener). She had several serum autoantibodies and a skin biopsy showed a foreign body granuloma. The diagnosis of adjuvant induced autoimmune/inflammatory syndrome was made. The pulmonary involvement was an atypical manifestation at the onset of disease.

© 2013 Elsevier España, S.L.U. All rights reserved.

Síndrome autoinmune/inflamatorio inducido por adyuvante que debuta con manifestaciones pulmonares y articulares

RESUMEN

Mujer de 59 años de edad, la cual cuenta con antecedente de aplicación de material oleoso en los glúteos hace 11 años; posteriormente hace 18 meses comienza con cuadro de poliartritis aditivas simétricas, así como afección en las vías aéreas superior e inferior, sin evidencia de alteración por granulomatosis con poliangeitis (Wegener). Presenta en suero autoanticuerpos, y se toma biopsia de piel donde se observa granuloma por cuerpo extraño. Se concluye con síndrome autoinmune/inflamatorio inducido por adyuvante, en el que la afección pulmonar es una manifestación atípica en la presentación inicial de la enfermedad.

© 2013 Elsevier España, S.L.U. Todos los derechos reservados.

Palabras clave:

Autoinmune

Adyuvante

Granulomatosis

Introduction

The autoimmune/inflammatory syndrome induced by an adjuvant is a condition characterized by the presence of various manifestations and/or non-specific symptoms, which can represent different rheumatological entities.^{1,2} Patients frequently have a history of applying a foreign substance to their body that can act as an adjuvant, such as unspecified materials for esthetic purposes.¹

Four conditions have been associated with this syndrome: silicosis, Gulf War syndrome, post-vaccination syndrome and macrophagic myofasciitis³ phenomenon; these entities have

recently been encompassed in the autoimmune/inflammatory syndromes induced by adjuvants.^{3,4} In our country there are several case series, which report this condition after the application of oily substances in their majority, of unspecified type and for esthetic purposes.¹

Clinical Observation

A 59-year-old housewife comes to the clinic due to pain in the lumbar region that precludes adequate gait. Family history of relevance was a daughter with rheumatoid arthritis and a sister who died of scleroderma complications. She denied smoking and uses alcohol occasionally. COMBE denied. Hypertension was diagnosed a year prior and treated with enalapril 10 mg PO every 12 h. She had a dislocated right elbow 9 months ago, with thoracolumbar trauma, treated conservatively. She denied allergy and transfusions. She refers an unspecified chemical injection in buttocks 11 years ago for esthetic purposes, subsequent degeneration of the

[☆] Please cite this article as: Flores Padilla G, Mora Mendoza B, Pedraza Montenegro A. Síndrome autoinmune/inflamatorio inducido por adyuvante que debuta con manifestaciones pulmonares y articulares. Reumatol Clin. 2014;10:406–408.

* Corresponding author.

E-mail address: axel09_p@hotmail.com (A. Pedraza Montenegro).

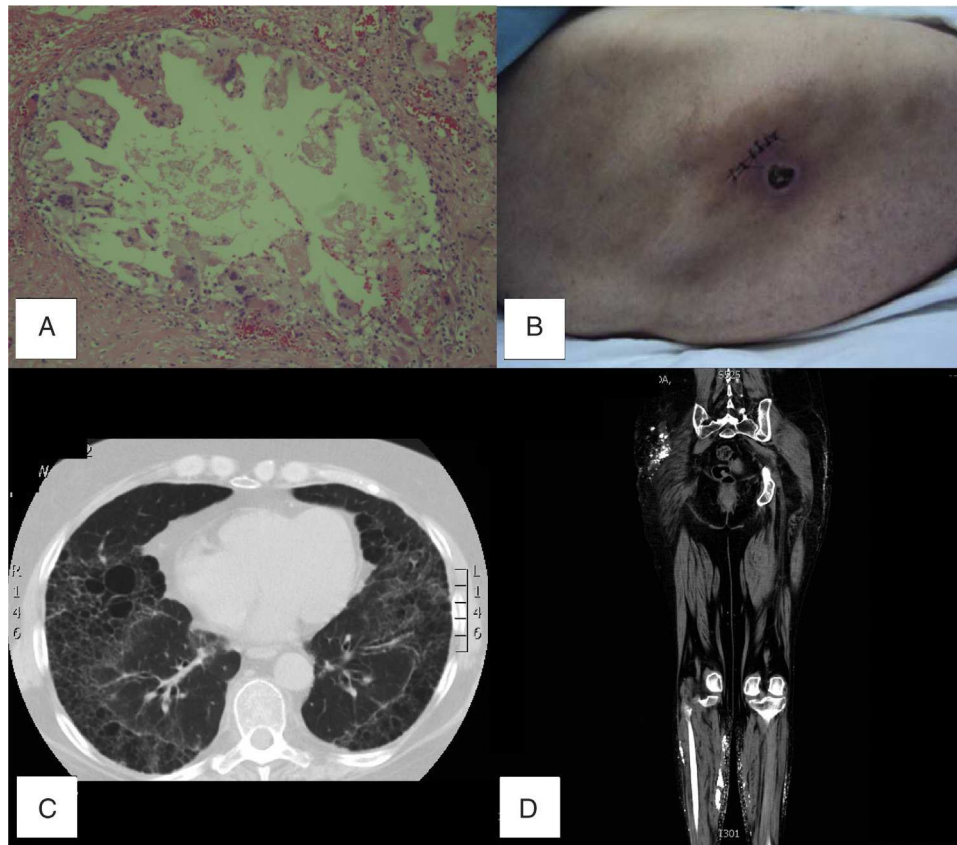


Fig. 1. (A) Skin biopsy of gluteal region with foreign body granuloma with calcifications, vascular proliferation, necrosis and areas of sclerosis. (B) Superficial skin necrosis, gluteal region, right side view. (C) Plain chest CT-AR, panlobular emphysema. (D) Lower limb CT, with confluent hyperdense nodular lesions in both buttocks that spread to the thigh and posterior leg region suggesting calcifications.

region with formation of superficial necrosis and calcification, as well as deformation and hardening.

She had polyarticular joint pain bilaterally and symmetrical, with increased volume and local temperature, lower limb edema and pain of the cervical spine for 18 months. She also presented lower airway disease and rhinitis, suggestive of infection. At the beginning we thought the patient presented granulomatosis with polyangiitis (Wegener), so we began treatment with prednisone at doses of 25 mg per day for about 6 months, and later was treated through homeopathy with “natural cortisol”, with partial remission.

Her current problem began 2 months ago with thoracolumbar pain, treated with non-steroidal anti-inflammatory drugs and centrally acting with partial remission. 7 days prior she had increased pain radiating to the right lower limb, accompanied by paresthesias and decreased strength on the same side due to persistent pain and decided to come to our unit.

The patient was conscious, oriented in time, place and person, with the presence of skin disease on the face with purplish malar erythema, subcutaneous nodular induration and telangiectasia, episcleritis of the left eye, skin hyperpigmentation and V lesions suggestive of venous angiomas, and bilateral painless mobile submandibular lymphadenopathy of less than 1 cm. She had rhythmic heart sounds, breath sounds presented symmetrical bilateral, interscapulovertebral, subcrepitant, and infrascapular rales. Her abdomen was soft, not painful and peristalsis was present. The right gluteal area lateral surface presented an area of necrosis (Fig. 1). Upper extremities presented disseminated ecchymosis and periungual punctate lesions, suggestive of necrosis; carpus and metacarpals were not painful or swollen, but there was pain on the proximal interphalangeal joints with 2 symmetrical painful but not swollen joints, mild ulnar deviation of the fingers that corrected

when placed on a hard surface, with limited range of motion in the shoulders. Intact lower extremities without edema, muscle stretch reflexes +/++++, muscle strength 4/5 bilaterally; tarsal, metatarsal and interphalangeal joints were normal.

The plain chest high-resolution tomography (CT-HR) showed panlobular emphysema (Fig. 1). Simple CT of the lower limbs demonstrated confluent hyperdense nodular lesions in both buttocks which spread to the thigh and posterior leg (Fig. 1 MRI of lumbar spine, herniated disc L4-L5). Densitometry was compatible with osteoporosis. Laboratory tests, C-reactive [PCR] erythrocyte sedimentation rate [ESR] and protein were slightly elevated, and autoimmune markers such as elevated rheumatoid factor and anti-cyclic citrullinated peptide antibodies (Table 1), suggested the presence of active autoimmune disease. Her thyroid profile had a biochemical pattern of subclinical hyperthyroidism (Table 1).

Discussion

It was initially considered that the patient had granulomatosis with polyangiitis (Wegener), due to the condition of the lower and upper respiratory tract; however, we concluded that there was no evidence of pulmonary vasculitis, but only a chronic condition, and no renal disease. Otorhinolaryngology considered that changes in nasal mucosa were not compatible with vasculitis. It was considered that the condition was dermal photosensitivity of the neck and face, as well as dermal and muscular reaction due to the application of adjuvant both in the face and buttocks.¹ The patient presented markers of inflammation (acute phase reactants, ESR and CRP) and autoimmunity (rheumatoid factor and anti-cyclic citrullinated peptide antibodies)⁵ (Table 1). The presence of rheumatoid factor,

Table 1
Results of Laboratory Tests.

Glucose	92 mg/dl
Urea	26 mg/dl
Creatinine	0.45 mg/dl
DHL	659 U/l
Sodium	137 mEq/l
Potassium	4.06 mEq/l
Chlorine	100 mEq/l
PT	12.8 s
APTT	23.8 s
Leukocytes	12 200 cells/mcL
Hemoglobin	15.1 g/dl
Platelets	357 000 mcl
Anti-DNA	7 U/ml (negative below 20)
ANA	Negative
C3	185
C4	36
IgM anticardiolipin Ab	2.3 (negative less than 13)
IgG anticardiolipin Ab	2.0 (negative below 20)
ESR	27
CRP	0.76 mg/dl (0–0.5)
TSH	1.81 McU/l (0.27–4.2)
Free T4	2.07 ng/dl (0.93–1.7)
Rheumatoid factor	192.7 U/ml (0–14)
Anti-CCP	More than 200 UI

ANA, antinuclear antibodies; Ab, antibodies; Anti-CCP, anti-CCP antibody; Anti-DNA, anti-DNA antibodies; DHL, lactic dehydrogenase; CRP, C-reactive protein; PT, prothrombin time; TSH, thyroid stimulating hormone; APTT, activated thromboplastin time; ESR, erythrocyte sedimentation rate.

Table 2
Suggested Criteria for Autoimmune/Inflammatory Syndrome Induced by Adjuvants.

1. History of the application of an external substance which acts as an adjuvant
2. Appearance of typical clinical manifestations:
Myalgia, myositis or muscle weakness
Joint pain and/or arthritis
Chronic fatigue, unrefreshing sleep or sleep disorders
Neurological manifestations (especially those related to demyelination)
Cognitive disorder, memory loss
Fever, dry mouth
3. Improvement by removing inducing agents
4. Biopsy of the affected tissue with typical findings
5. Biochemical markers of autoimmune disease (RF, Anti-CCP, Anti-DNA, etc.)

Anti-CCP, anti-CCP antibody; Anti-DNA, anti-DNA antibodies; RF, rheumatoid factor. Source: Meroni.²

polyarticular joint pain and anti-cyclic citrullinated peptide antibodies suggested rheumatoid arthritis, and considering the start of manifestations in years after the implementation of the adjuvant, we considered it as part of the autoimmune/inflammatory syndrome induced by adjuvant. Partial attenuation induced by the use of glucocorticoids was seen, but she was still a candidate for surgical treatment due to the extension and migration of the calcifications.¹ Skin biopsy of the gluteal region reported granulomatous foreign body reaction with calcifications, vascular proliferation, necrosis and areas of sclerosis¹ (Fig. 1).

Conclusion

The patient presented an autoimmune/inflammatory syndrome induced by an adjuvant, fulfilling the criteria suggested for this entity^{1,3,4} (Table 2), such as the presence of rheumatoid arthritis with onset after the application of the adjuvant and clinical manifestations such as arthritis and ischemia, autoimmune markers (rheumatoid factor and anti-cyclic citrullinated peptide antibodies), a history of the application of a foreign substance (probably oil) which acts as an adjuvant itself and the histological demonstration of granulomatous inflammation and foreign body reaction in the relevant affected areas. None of the reported cases have shown lung disease as the first manifestation in the series of this syndrome,¹ although, as described in this case, it may occur in rheumatoid arthritis, although the initial debut as presented here, associated with autoimmune/inflammatory syndrome induced by adjuvant, had not been described before. It is noteworthy that the criteria proposed in previous publications for this syndrome requires acceptance by the relevant international organizations for adequate definition of the disease.⁶

Conflicts of Interest

The authors have no conflicts of interest.

Ethical Responsibilities

Protection of people and animals. The authors declare that this research has not performed experiments on humans or animals.

Data privacy. The authors declare that they have followed the protocols of their workplace on the publication of data from patients and all patients included in the study have received sufficient information and gave written informed consent to participate in the study.

Right to privacy and informed consent. The authors state that patient data does not appear in this article.

References

- Vera-Lastra O, Medina G, Cruz-Domínguez M del P, Ramírez P, Gayosso-Rivera JA, Anduaga-Domínguez H, et al. Human adjuvant disease induced by foreign substances: a new model of ASIA (Shoenfeld's syndrome). *Lupus*. 2012;21:128–35.
- Meroni PL. Autoimmune or auto-inflammatory syndrome induced by adjuvants (ASIA): old truths and a new syndrome? *J Autoimmun*. 2011;36:1–3.
- Shoenfeld Y, Agmon-Levin N. 'ASIA' – Autoimmune/inflammatory syndrome induced by adjuvants. *J Autoimmun*. 2011;3:4–8.
- Toubi E. ASIA – Autoimmune syndromes induced by adjuvants: rare, but worth considering. *Isr Med Assoc J*. 2012;14:121–4.
- Selmi C, Leung P, Sherr D, Díaz M, Nyland JF, Monestier M, et al. Mechanisms of environmental influence on human autoimmunity: a national institute of environmental health sciences expert panel workshop. *J Autoimmun*. 2012;39:272–84.
- Agmon-Levin N, Hughes GRV, Shoenfeld Y. The spectrum of ASIA: autoimmune (auto-inflammatory) syndrome induced by adjuvants. *Lupus*. 2012;21:118–20.