



Sociedad Española
de Reumatología -
Colegio Mexicano
de Reumatología

Reumatología Clínica

www.reumatologiaclinica.org



Images in Clinical Rheumatology

Granuloma Annular-like Lesions as a Manifestation of Eosinophilic Granulomatosis With Polyangiitis[☆]



Lesiones granuloma anular-like como manifestación cutánea de granulomatosis eosinofílica con poliangiitis

Belén Lozano-Masdemont,^{a,*} Celia Horcajada-Reales,^a Laura Gómez-Recuero Muñoz,^a Verónica Parra-Blanco^b

^a Departamento de Dermatología, Hospital General Universitario Gregorio Marañón, Madrid, Spain

^b Departamento de Pathología, Hospital General Universitario Gregorio Marañón, Madrid, Spain

ARTICLE INFO

Article history:

Received 6 June 2016

Accepted 21 July 2016

Available online 14 July 2017

Introduction

Eosinophilic granulomatosis with polyangiitis (EGPA) is a systemic vasculitis that is commonly associated with cutaneous involvement (40%–81%).^{1–3}

Case Report

The patient was a 53-year-old man with a history of rhinitis, asthma and eosinophilic pneumonia, diagnosed 4 years earlier, who presented with pruritic lesions on the scalp that had developed 7 days before. There were 4 circular plaques measuring 2–4 cm, that were skin-colored or erythematous, with an infiltrated border and small scabs (Fig. 1A and C). Biopsy revealed a superficial inflammatory infiltrate made up of lymphocytes and eosinophils; there were neutrophils in the vessel wall, with no fibrinoid necrosis; we also detected histiocytes interspersed with degenerated collagen in the superficial and reticular dermis (Fig. 1B). Direct immunofluorescence and Ziehl-Neelsen staining were negative. We found leukocytosis with 15,900 cells/ μ L; eosinophilia (24.7%;

3900 cells/ μ L); and complement C3 of 83.7 mg/dL. Antinuclear antibodies, antineutrophil cytoplasmic antibodies (perinuclear ANCA and cytoplasmic ANCA) and urinalysis were normal. The diagnosis was EGPA, which ruled out cardiac and renal involvement. The patient was receiving prednisone at 10 mg/day for a respiratory disease; the dose was increased to 30 mg/day for 2 weeks, and resolution was achieved. During the last 6 months, he had a relapse in the form of parietal urticarial plaques, which were satisfactorily treated with a topical corticosteroid.

Discussion

The most common lesions in EGPA are papules and nodules, palpable purpura and vesicles or blisters. The histological findings consist in extravascular granulomas (50%), with distinct clinical manifestations, followed by leukocytoclastic vasculitis.¹ Churg-Strauss granuloma can be interstitial at first and subsequently be palisaded. The interstitium is characterized by epithelioid histiocytes intermingled with degenerated collagen and an inflammatory infiltrate with neutrophils, lymphocytes and eosinophils. The palisaded granuloma show images of leukocytoclastic vasculitis and degenerated collagen, with epithelioid histiocytes, multinucleated giant cells and eosinophils.^{4–6}

The clinical signs of EGPA currently described do not include plaques mimicking granuloma annulare: this case reflects an unknown manifestation and points out the changing nature of these lesions, toward urticarial plaques.

[☆] Please cite this article as: Lozano-Masdemont B, Horcajada-Reales C, Gómez-Recuero Muñoz L, Parra-Blanco V. Lesiones granuloma anular-like como manifestación cutánea de granulomatosis eosinofílica con poliangiitis. Reumatol Clin. 2017;13:357–358.

* Corresponding author.

E-mail address: belenmasdemont@gmail.com (B. Lozano-Masdemont).

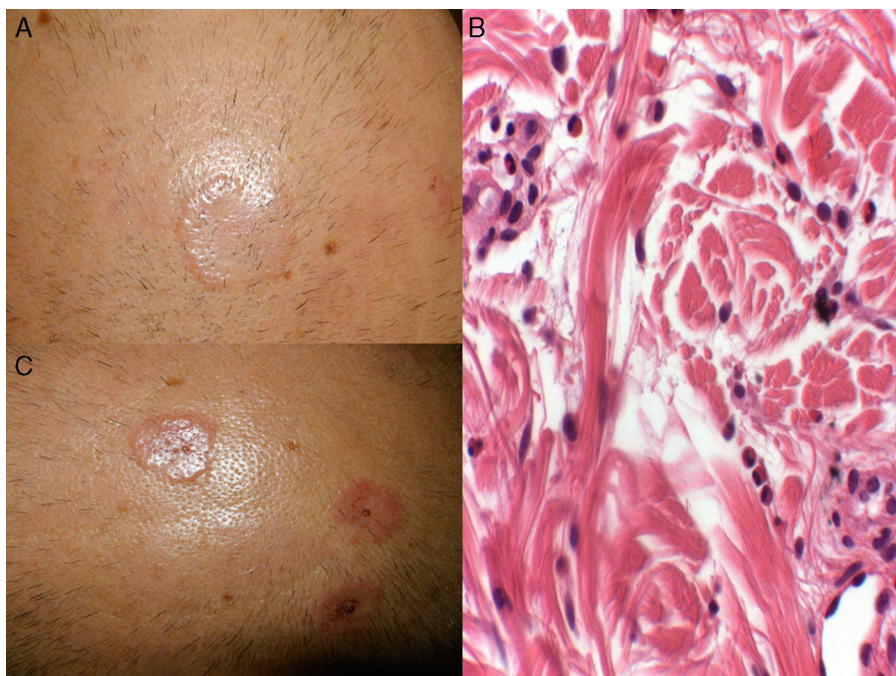


Fig. 1. (A and C) Circular, skin-colored and erythematous plaques measuring 2–4 cm, with a more infiltrated border and small scabs on the surface. (B) Histiocytes interspersed with bundles of degenerated collagen accompanied by an inflammatory infiltrate with abundant eosinophils (hematoxylin-eosin, 20 \times).

Ethical Disclosures

Protection of human and animal subjects. The authors declare that no experiments were performed on humans or animals for this study.

Confidentiality of data. The authors declare that they have followed the protocols of their work center on the publication of patient data.

Right to privacy and informed consent. The authors have obtained the written informed consent of the patients or subjects mentioned in the article. The corresponding author is in possession of this document.

Funding

None.

Conflicts of Interest

The authors declare they have no conflicts of interest.

References

1. Bosco L, Peroni A, Schena D, Colato C, Girolomoni G. Cutaneous manifestations of Churg-Strauss syndrome: report of two cases and review of the literature. *Clin Rheumatol.* 2011;30:573–80.
2. Jennette JC, Falk RJ, Bacon PA, Basu N, Cid MC, Ferrario F, et al. 2012 revised International Chapel Hill Consensus Conference Nomenclature of Vasculitides. *Arthritis Rheum.* 2013;65:1–11.
3. Masi AT, Hunder GG, Lie JT, Michel BA, Bloch DA, Arend WP, et al. The American College of Rheumatology 1990 criteria for the classification of Churg-Strauss syndrome (allergic granulomatosis and angiitis). *Arthritis Rheum.* 1990;33:1094–100.
4. Strauss L, Churg J, Zak F. Cutaneous lesions of allergic granulomatosis: a histopathologic study. *J Invest Dermatol.* 1951;17:349–59.
5. Lynch JM, Barrett TL. Collagenolytic (necrobiotic) granulomas: part II – the ‘red’ granulomas. *J Cutan Pathol.* 2004;31:409–18.
6. Dicken CH, Winkelmann RK. The Churg-Strauss granuloma: cutaneous, necrotizing, palisading granuloma in vasculitis syndromes. *Arch Pathol Lab Med.* 1978;102:576–80.